



Cognitive and histopathological effects of olive leaf extract in colchicine-induced hippocampal neurodegeneration in rats

Marwan Saad Azzubaidi¹, Harmacy Bin Mohamed Yusoff¹, Imad Matloub Al-Ani²

¹Pharmacology Unit, Faculty of Medicine, Universiti Sultan Zainal Abidin, Kampus Kota, Kuala Terengganu, Malaysia

²Department of Dentistry, Al-Hadi University College, Baghdad-10011, Iraq

ARTICLE INFO

Article Type:
Original Article

Article History:
Received: 2 February 2023
Accepted: 29 April 2023

Keywords:
Drug-induced
Neurodegeneration
Olive leaf
Neuroprotection
Hippocampus

ABSTRACT

Introduction: Olive leaf extract (OLE) has robust anti-oxidant and anti-inflammatory properties. A toxic dose of colchicine (COL) injected into the hippocampus disrupts the microtubules' neuronal structure causing it to be unstable and depolymerized. The objective of the current study was to evaluate the protective effects of OLE treatment on the CA1 hippocampal pyramidal cells of rats that are injected with intracranial COL.

Methods: Eighteen rats were divided into control, COL-injected, and OLE-treated-colchicine-injected (COL+OLE) groups (n=6). A vehicle solution was injected into the hippocampi of the control rats, whereas 15 µg/5 µL of COL was injected into the hippocampi of COL and COL+OLE groups. Forced oral treatment with 100 mg/kg OLE was commenced a week later and continued for 15 days. Short-term memory (STM) test using the Morris water maze (MWM) was performed followed by the retention probe memory test. Hippocampal samples from animals of all groups were collected for histopathological examination and qualitative assessment of the viable pyramidal cells at the CA1 hippocampal region.

Results: The control and COL+OLE groups demonstrated significantly better performance ($P < 0.05$) in the STM test and its subsequent retention probe memory test as compared to the COL group. The morphology of the pyramidal cells of the COL+OLE treated rats was preserved, showing less distortion than the COL group.

Conclusion: OLE treatment led to a considerable preservation in the STM function of rats challenged with intrahippocampal COL injection. This memory improvement of the OLE might be attributed to its promising neuroprotective potential on hippocampal pyramidal cells.

Implication for health policy/practice/research/medical education:

OLE seems to have a considerable neuroprotective effect on hippocampal pyramidal cells improving memory improvement potential. More extensive evidence-based research is required to authenticate and screen its medicinal benefits and compare the biological activities of its active ingredients for the prevention and treatment of various diseases, including age-related neurodegeneration.

Please cite this paper as: Azzubaidi MS, Yusoff HM, Al-Ani IM. Cognitive and histopathological effects of olive leaf extract in colchicine-induced hippocampal neurodegeneration in rats. J Herbm Pharm. 2023;12(3):442-447. doi: 10.34172/jhp.2023.49.

Introduction

Olive tree (*Olea europaea* L.) is one of the oldest agricultural tree crops and has been a primary source of oil for centuries. It has been cultivated widely since prehistoric times in the Mediterranean region, the Indian subcontinent, and Asia. Because of its close association with human religion, culture, medicine, and nutrition, the leaves of the olive tree have been used as a traditional

herbal tea for its beneficial effects among people around the Mediterranean basin (1). Olive leaf extract (OLE) has been the subject of several recent studies due to its potential beneficial effects on human health as it bears anti-oxidant, anti-atherosclerotic, cardioprotective, and hypoglycaemic effects. The consumption of OLE was reported to be associated with a lower incidence of cardiovascular diseases, such as hypertension and metabolic syndrome,

*Corresponding author: Marwan Saad Azzubaidi, Email: mazzubaidi@gmail.com, mazzubaidi@unisza.edu.my

including diabetes and hyperlipidaemias (2). Moreover, memory-enhancing effects of OLE have been claimed in animal experiments (3).

Oxidative stress is a condition created by the imbalance between oxidants and antioxidants in a biological system. The imbalance occurs due to the excess level of reactive oxygen species (ROS) or improper functioning of the antioxidant system. Elevated levels of ROS and a decrease in antioxidants disturb cellular homeostasis, leading to harmful effects on biomolecules and causing various age-related pathologies and diseases such as cancer, cardiovascular, and neurodegenerative diseases (4).

Colchicine (COL) is an alkaloid extracted from the plants of the genus *Colchicum* (*Autumn crocus*). COL is a microtubule-disrupting agent that produces marked destruction of hippocampal granule cells, mossy fibres, and septohippocampal pathways. It induces neurofibrillary degeneration by binding to tubulin, the structural protein of the microtubule, which is associated with the loss of cholinergic neurons and a decrease in acetylcholine-transferase resulting in impairment of learning and memory.

COL-induced cognitive impairment has been established as an animal model of sporadic dementia of Alzheimer's type (5). It causes instability and depolymerization of the microtubules and inhibits axonal conduction, eventually leading to the death of the nervous cells (6). Alzheimer's disease is associated with microtubule dysfunction and is characterized by the appearance of specific cytoskeletal cellular abnormalities, which are associated with cognitive impairment (5).

Since the Morris water maze (MWM) is an established paradigm for assessing the cognitive memory performances in rats with chronic cerebral neurodegeneration (7,8), therefore, this study aimed to study the neuroprotective and therapeutic effects of OLE on COL-induced neurodegeneration by assessing the short-term memory (STM) levels of animals using MWM test.

Materials and Methods

Methanolic extraction of OLE

One kilogram of olive leaves was morphologically authenticated at the pharmacognosy lab by Dr. Norazian Mohd Hassan, Faculty of Pharmacy, IIUM. A specimen

was archived at the faculty herbarium with the specimen number (MH-1344-OL/KOP). The overnight air-dried olive leaves were ground into fine powder and added to 5 L of 80% methanol. The mixture was then filtered after 24 hours. The filtrate was then concentrated to yield a solid extract under a reduced-pressure rotary evaporator. After freeze-drying, the OLE was stored in a fridge at 7°C until it was used for forced oral treatment. The yield of OLE was 39.64 grams. The solid extract was dissolved in deionized water before oral treatment (9).

Animals

Eighteen male Sprague Dawley rats weighing 255-360 g were equally divided into three groups; control group (injected with artificial CSF only), colchicine-injected (COL) group, and 100 mg/kg OLE-treated-colchicine-injected (COL+OLE) group. The rats were housed in standard cages in a controlled colony room ($21 \pm 3^\circ\text{C}$). They were maintained under a 12:12 hours light/dark cycle with access to tap water and food pellets *ad libitum*. All procedures complied with the good laboratory practice guidelines of animal handling and were approved by UniSA pre-clinical animal research ethical committee with the reference number (EA-20-FP-122/L-03). The COL and COL+OLE groups were injected with 15 μg COL dissolved in 5 μL artificial CSF via an intracerebral hippocampal single injection. The treatment with OLE started a week after the injection and continued for 15 days via forced oral feeding. Distilled water was forced orally into the control and COL groups. The experimental design of the study is shown in Figure 1.

Apparatus

A 2-meter diameter black fiberglass circular tank, 60 cm in height, filled with water up to 30 cm, was used (Figure 2). The escape platform (EP) was a black 10 cm diameter cylinder. Water temperature was maintained at 26°C throughout the test period. Colored posters were pasted on the surrounding walls near the tank for the rats to develop spatial memory. ANY-maze video tracking software (Stoelting Co., USA) was used to record the swimming time of the rats. Four hypothetical points (N, S, E, and W) depicted the swim starting point of the rats for the four daily tests. The starting point was not repeated

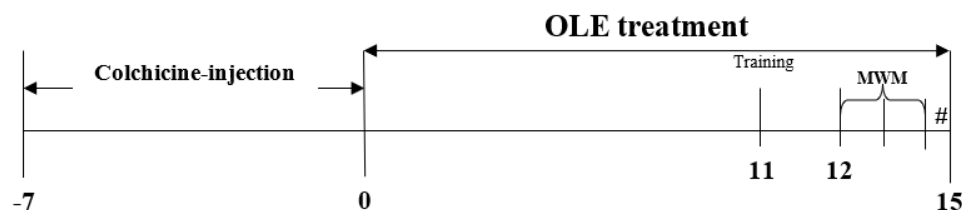


Figure 1. Experimental design of the study groups. OLE treatment was started a week after colchicine injection into the hippocampus. Habituation training was performed on day "11". The STM test was started on day "12" for three successive days, followed by the # probe retention test on day "15".




Figure 2. Image depicting Morris water maze pool as viewed from above. The four starting points: N, S, E, and W, were randomly chosen for the training and trials. EP was the target rescue area. The probe memory test started from the SE quadrant (arrowhead). N= north, S= south, E= east, W= west, EP= escape platform, NE= northeast, SE= southeast, SW= south west, and NW= northwest.

for subsequent days of trial. The pool was divided into four virtual quadrants: NE, SE, SW, and NW, as shown in Figure 2.

The habituation training session was done on the 11th day of treatment. The STM test paralleled the last three days of OLE treatment according to the protocol previously described by Azzubaidi et al (10). Each animal attempted four daily swimming trials with visible EP for three successive days. A probe test was done on day 15 with the EP removed from the pool; each animal was given a maximum time of 60 seconds starting from the SE pole. The number of annulus crossings was recorded.

Colchicine-injection procedure

The procedure was done under aseptic conditions. Intraperitoneal sodium pentobarbital 30 mg/kg was injected. A 2 cm longitudinal midline skin incision was made on the rat's scalp. Fifteen micrograms COL dissolved in 5 μ L artificial CSF (11) was slowly injected into left and right hippocampi using an insulin syringe for the COL and COL+OLE groups. Artificial CSF was injected into the rat's hippocampus of the control group. The cranial landmark for intrahippocampal injection was 2 mm anterior to the lambdoid suture along the sagittal suture and then 2.25 mm lateral to the sagittal suture on both sides (Figure 3). The skin incision was sutured with a non-absorbable suture. Postoperative diclofenac sodium 10 mg/kg analgesic was injected intraperitoneally to reduce the post-operative pain.

Histological study

The animals were euthanized with an overdose of inhaled diethyl ether solution after four weeks of COL intracranial injection. Rat brains were quickly excised and dissected

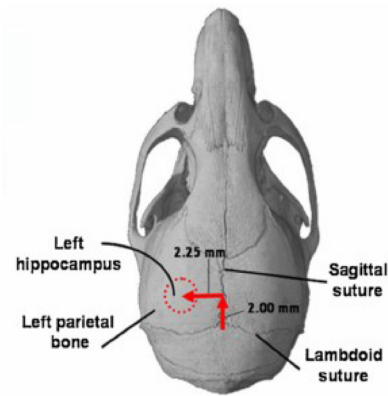


Figure 3. Hippocampus anatomical landmark.

on an ice-cold metal plate. The right hemispheres were grossly dissected 3 mm posterior to the lower end of the fornix, as previously described previously (12). After a 72-hour fixation in 10% formaldehyde solution, staining with cresyl violet was done on 5 mm thickness sectioned slides for viewing under light microscopy.

Statistical analysis

Results were expressed as mean \pm standard error of the mean (SEM). Two-way analysis of variance (ANOVA) with repeated measures was used to analyse the significant difference in escape latency and body weight of rats per week. Post hoc comparison (Tukey HSD's test) was utilized to determine the overall significance of treatment as compared to the control and COL groups. One-way ANOVA was employed to analyse the probe memory test. *P* value less than 0.05 ($P < 0.05$) was considered statistically significant.

Results

Short-term memory test findings

STM test results on days 12–14 of the treatment with OLE indicated a significant difference ($P < 0.05$) of the control and COL+OLE groups compared to the COL group. On day "14", the control and COL+OLE groups demonstrated a significantly faster ($P < 0.05$) escape latency than the COL group. The escape latency values on day "14" for control, COL, and COL+OLE were 11.38 ± 0.17 , 60.00 ± 0.19 , and 29.25 ± 0.19 seconds, respectively (Figure 4).

Probe memory test findings

The number of annuli crossing the EP zone for the control, COL, and COL+OLE groups was 4.00 ± 0.447 , 1.00 ± 0.00 , and 2.00 ± 0.00 , respectively. The COL+OLE group revealed a statistically significant difference ($P < 0.05$) when compared with the control group (Figure 5).

Histological observation

Morphologically, the CA1 hippocampal region of the

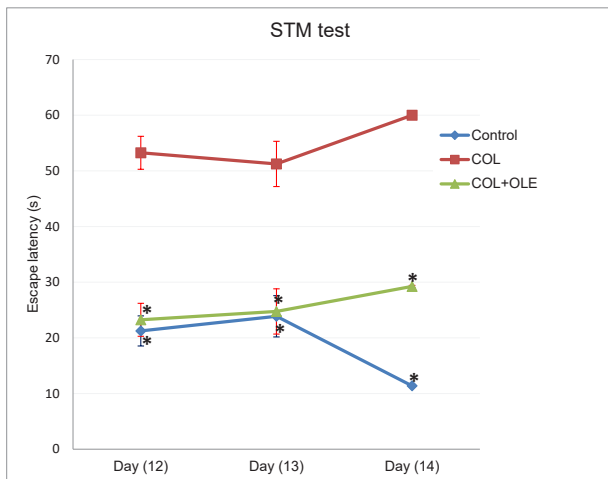


Figure 4. Line graph depicting significant intergroup differences in escape latency for three successive days (12, 13, and 14). COL+OLE and control groups demonstrated a significantly faster escape latency than the COL-injected group. * $P < 0.05$ as compared to the COL group. OLE: Olive leaf extract; COL: Colchicine.

control group showed typical pyramidal cells with well-demarcated cell membranes, clear cytoplasm, and a well-delineated nucleus. These were normal findings for the viable neurons in the control group (Figure 6a). However, in the COL-injected animal group, the toxic effect of the COL on the pyramidal cells manifested itself histopathologically as distorted shrunken pyramidal (non-viable) cells with irregular boundaries. The presence of dark cytoplasm and indistinct pyknotic nuclei of the pyramidal neurons of the CA1 layer in the COL-injected group proves that

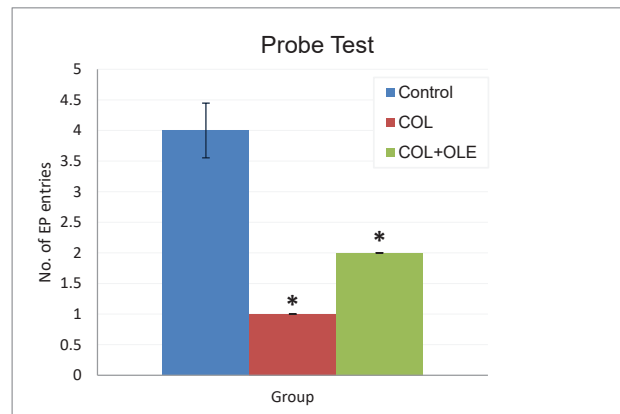


Figure 5. Histogram depicting the (day 15) probe memory test findings represented by the number of annuli crossings the escape platform zone within 60 seconds. * $P < 0.05$ versus the control group. OLE: Olive leaf extract; COL: Colchicine.

a neurodegenerative process has taken place as a result of COL toxicity (Figure 6b). Moreover, treatment with OLE improved the pyramidal cell morphology in COL+OLE-treated rat hippocampal sections with apparent and well-demarcated nuclei (Figure 6c).

Discussion

This study was designed to investigate potential neuroprotective effect of olive leaf methanolic extract on the COL-induced neurodegeneration of the rat brain. This work's findings confirmed COL's detrimental effect on the pyramidal cell layers in the CA1 area of the hippocampus, thus supporting the conclusion of previous

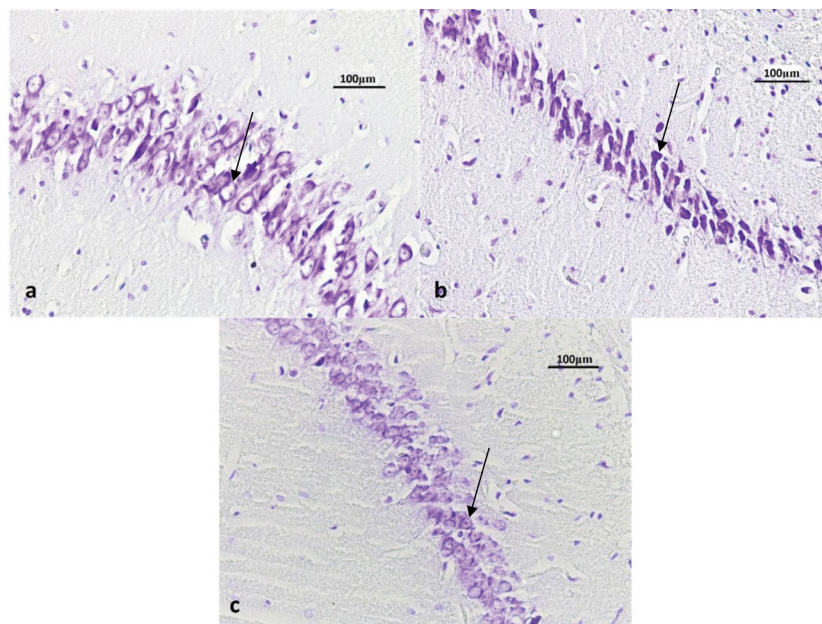


Figure 6. Cresyl violet stained light microscopy photomicrographs defining the CA1 hippocampal region showing the pyramidal neurons (arrows) of (a) the control group, depicting the typical shape of pyramidal neurons and a distinct nucleus and a clear cytoplasm (b) Colchicine (COL)-injected group, depicting shrunken distorted cell with an indistinct nucleus that cannot be differentiating from the cytoplasm (c) COL+OLE treated group, depicting pyramidal neurons that are partially contracted with an overall preserved nucleus indicating cellular viability. OLE: Olive leaf extract.

studies that COL neuronal toxicity irreversibly damages dendrites by disrupting their microtubules supporting network (6). COL toxicity mimics Alzheimer's disease pathogenesis in several mechanisms, such as disrupting the neuronal microtubule structure causing it to be unstable and depolymerized, eventually leading to the necrosis of the neurons. Besides the CA1 hippocampal neurodegeneration, the granular cell layer in the dentate gyrus is lost (13). The intrahippocampal COL injection into the rats was found to cause cognitive deficits similar to those of Alzheimer's disease. These features are manifested by learning defects and impairment of recent memories, which have been consolidated (11). Furthermore, COL is reported to increase the level of free radicals, thereby aggravating the oxidative stress status and simultaneously decreasing the glutathione level, which is an essential antioxidant in the body. Consequently, necrosis of the pyramidal cells in the hippocampus is inevitable (5). Moreover, other studies have affirmed that the intracranial COL injection would significantly weaken memory secondary to a reduction of neurotransmitters levels, such as norepinephrine, dopamine, and serotonin in the cerebral cortex, hippocampus, and the caudate nucleus, which ultimately leads to learning difficulties (11).

The daily oral treatment of 15 mg/kg OLE markedly ameliorated the histopathological changes in the hippocampal pyramidal cells and showed less overall neuronal cell loss. This might be attributed to the potent antioxidant, free radical scavenging, and anti-inflammatory properties of OLE, which play an essential role in preventing neuronal damage from toxic free radicals' effect and oxidative stress caused by COL. Previous studies have reported that free radicals' deleterious effects can mediate necrosis and neuronal degeneration in brain regions abundant with such ROS (14). It is well-known that oxidative stress is involved in neuronal cell death, which is associated with neurodegenerative disorders such as AD. Researchers have shown that COL derivatives could augment ROS to the level that can activate apoptosis in cancerous lymphocytes (15).

The retention probe memory test on the following day confirmed the considerable deterioration in memory water maze performance by the COL group between the 12th and the 14th days of the study. Animals of the COL group swam by circling the edge of the pool, and there was a time when rats failed to find the platform. Therefore, the number of annulus crossings in the EP zone was significantly worse than the control group. Although it is observed that the level of improvement in escape latency pattern with the OLE-treated group was not as robust as it was reported in the previous study with the use of *Nigella sativa* treatment on spatial cognitive functions in the study done by Azzubaidi and colleagues (10), yet the escape latency time for the three trials was significantly faster than COL group. Nevertheless, the preservation of cognitive function by

OLE treatment was proved as it performed well on the day of the probe memory test. The animal learning behavior was observed in the COL+OLE-treated group; i.e., the rats in the OLE-treated group showed a rearing behavior after climbing the platform. Animals were noticed to keep looking around at the surrounding cues, which indicates the learning process. Unlike the OLE-treated group, the COL group was not observed to swim to the EP zone group, only after spending significant time swimming away from the EP quadrant. These improvements in the OLE-treated rats may be related to the neuroprotective effect of OLE and its antioxidant properties. The histological observation of the CA1 area proved that there was a neurodegenerative process affecting the pyramidal neurons of the hippocampus in COL group rats. Electron microscopic assessment is in progress to study the detailed ultrastructural changes that occurred in the COL and COL+OLE groups.

The phenolic compounds that form the active constituents of the olive leaf, such as oleuropein, hydroxytyrosol, flavones, flavonols, and flavan-3-ols, contribute to OLE's robust antioxidant activity (16). Oleuropein was reported to reduce lipid peroxidation activity in the oleuropein-treated group (2). Oleuropein in olive leaf might exhibit its antioxidant activity by increasing superoxide dismutase activity and glutathione peroxidase activity in the oleuropein-treated group (17). Other *in vivo* studies have demonstrated that hydroxytyrosol, a phenolic compound extracted from the olive leaf and oil, possesses antioxidant and anti-inflammatory properties (18), besides reducing the levels of A β plaques in an AD mice model (19). Moreover, OLE was observed to relieve oxidative stress and hippocampal neuronal damage in transient cerebral ischemia (16). Additionally, OLE at doses ranging between 50 and 200 mg/kg has proved to possess anti-inflammatory and analgesic activities in a dose-dependent manner (20). OLE may exert its neuroprotective effect against amyloid toxicity by directly interfering with the aggregation process, thus inhibiting the formation of toxic soluble oligomers and amyloid fibrils. Cell viability is seen to be preserved with OLE since it interferes with the initiation of the amyloid aggregation process. As a result of decreasing the level of the toxic oligomer, the noxious effect of the amyloid fibrils on the brain is alleviated (21).

Conclusion

OLE treatment led to a considerable preservation in the STM function of rats challenged with intrahippocampal COL injection. This memory improvement of the OLE might be attributed to its promising neuroprotective potential on hippocampal pyramidal cells.

Acknowledgement

The authors thank UniSZA Research Center for

sponsoring this study under research grant number (EDW-B-2015-2845). Furthermore, the authors pay their tributes to the efforts of Dr. Norazian Mohd Hassan for authenticating the leaves and supervising the extraction process.

Conflict of interests

The authors declare no conflict of interest during and after conducting this research.

Authors' contributions

AMS was the principal designer of the experimental research, supervisor, and the core contributor to the manuscript write-up. HB MY was the second leading contributor to the research methodology and the statistical analyses. IAA was the researcher in charge of histopathological comparison among the different groups.

Ethical considerations

All procedures complied with the good laboratory practice guidelines of animal handling and have been approved by UniSZA pre-clinical animal research ethical committee with the reference number (EA-20-FP-122/L-03).

Funding/Support

The authors thank UniSZA Research Center for sponsoring this study under research grant number (EDW-B-2015-2845).

References

- Sabry OM. Review: beneficial health effects of olive leaves extracts. *J Nat Sci Res.* 2014;4(19):1-9.
- El SN, Karakaya S. Olive tree (*Olea europaea*) leaves: potential beneficial effects on human health. *Nutr Rev.* 2009;67(11):632-8. doi: 10.1111/j.1753-4887.2009.00248.x.
- Azzubaidi MS. Neuroprotective effect of olive leaf extract in colchicine-induced neurodegeneration. In: *The Fifth International Mediterranean Symposium on Medicinal and Aromatic Plants.* Cappadocia, Turkey: Dilek Kaya & Burcu Kaya Hotels; 2019.
- Singh A, Kukreti R, Saso L, Kukreti S. Oxidative stress: a key modulator in neurodegenerative diseases. *Molecules.* 2019;24(8):1583. doi: 10.3390/molecules24081583.
- Kumar A, Dogra S, Prakash A. Protective effect of naringin, a citrus flavonoid, against colchicine-induced cognitive dysfunction and oxidative damage in rats. *J Med Food.* 2010;13(4):976-84. doi: 10.1089/jmf.2009.1251.
- Naseri A, Karami M, Jalali Nadoushan MR, Riahi Zaniani N. Toxic effect of colchicine on hippocampal cortical area. *J Basic Clin Pathophysiol.* 2014;2(2):51-6.
- Azzubaidi MS, Al-Ani IM, Saxena AK, Faisal GG. Prevention of brain hypoperfusion-induced neurodegeneration in rat's hippocampus by black cumin fixed oil treatment. *Int Med J Malays.* 2018;17(1):103-12. doi: 10.31436/imjm.v17i1.309.
- Azzubaid MS, Al-Ani IM. Mnemonic and histopathological assessment of the neuroprotective effects of *Murraya koenigii* leaves extract in rats with partial global cerebral ischaemia. *Int Med J Malays.* 2019;18(2):77-86. doi: 10.31436/imjm.v18i2.93.
- Wang Y, Wang S, Cui W, He J, Wang Z, Yang X. Olive leaf extract inhibits lead poisoning-induced brain injury. *Neural Regen Res.* 2013;8(22):2021-9. doi: 10.3969/j.issn.1673-5374.2013.22.001.
- Azzubaidi MS, Saxena AK, Talib NA, Ahmed QU, Dogarai BB. Protective effect of treatment with black cumin oil on spatial cognitive functions of rats that suffered global cerebrovascular hypoperfusion. *Acta Neurobiol Exp (Wars).* 2012;72(2):154-65.
- Ganguly R, Guha D. Alteration of brain monoamines & EEG wave pattern in rat model of Alzheimer's disease & protection by *Moringa oleifera*. *Indian J Med Res.* 2008;128(6):744-51.
- Azzubaidi MS, Saxena AK, Talib NA. Quantifying dorsal hippocampal CA1 pyramidal cells in rats: rules to light microscope based estimation. *Malays J Microsc.* 2013;9(1):165-9.
- Nakayama T, Sawada T. Involvement of microtubule integrity in memory impairment caused by colchicine. *Pharmacol Biochem Behav.* 2002;71(1-2):119-38. doi: 10.1016/s0091-3057(01)00634-7.
- Andersen JK. Oxidative stress in neurodegeneration: cause or consequence? *Nat Med.* 2004;10 Suppl:S18-25. doi: 10.1038/nrn1434.
- Aghvami M, Eshghi P, Zarei MH, Arefi H, Sattari F, Zarghi A, et al. Novel colchicine analogues target mitochondrial PT pores using free tubulins and induce ROS-mediated apoptosis in cancerous lymphocytes. *Iran J Pharm Res.* 2018;17(4):1476-87.
- Dekanski D, Selaković V, Piperski V, Radulović Z, Korenić A, Radenović L. Protective effect of olive leaf extract on hippocampal injury induced by transient global cerebral ischemia and reperfusion in *Mongolian gerbils*. *Phytomedicine.* 2011;18(13):1137-43. doi: 10.1016/j.phymed.2011.05.010.
- Sarbishegi M, Mehraein F, Soleimani M. Antioxidant role of oleuropein on midbrain and dopaminergic neurons of substantia nigra in aged rats. *Iran Biomed J.* 2014;18(1):16-22. doi: 10.6091/ibj.1274.2013.
- Peng Y, Hou C, Yang Z, Li C, Jia L, Liu J, et al. Hydroxytyrosol mildly improve cognitive function independent of APP processing in APP/PS1 mice. *Mol Nutr Food Res.* 2016;60(11):2331-42. doi: 10.1002/mnfr.201600332.
- Nardiello P, Pantano D, Lapucci A, Stefani M, Casamenti F. Diet supplementation with hydroxytyrosol ameliorates brain pathology and restores cognitive functions in a mouse model of amyloid- β deposition. *J Alzheimers Dis.* 2018;63(3):1161-72. doi: 10.3233/jad-171124.
- Chebbi Mahjoub R, Khemiss M, Dhidah M, Dellaï A, Bouraoui A, Khemiss F. Chloroformic and methanolic extracts of *Olea europaea* L. leaves present anti-inflammatory and analgesic activities. *ISRN Pharmacol.* 2011;2011:564972. doi: 10.5402/2011/564972.
- Diomede L, Rigacci S, Romeo M, Stefani M, Salmona M. Oleuropein aglycone protects transgenic *C. elegans* strains expressing A β 42 by reducing plaque load and motor deficit. *PLoS One.* 2013;8(3):e58893. doi: 10.1371/journal.pone.0058893.