



Toxicity studies of *Acacia nilotica* (L.): A review of the published scientific literature

Lawaly Maman Manzo^{1,2*}, Idrissa Moussa², Khalid Ikhiri², Liu Yu¹

¹National Experimental Teaching Center of Biopharmaceuticals, Department of Biochemistry, China Pharmaceutical University, Nanjing 210009, PR China

²National Key Laboratory of Natural Substances, Department of Chemistry, University Abdou Moumouni of Niamey (UAM), Niamey B.P: 237, Niger

ARTICLE INFO

Article Type:
Review

Article History:
Received: 24 November 2018
Accepted: 8 March 2019

Keywords:
Medicinal plants
Acacia nilotica
Organ toxicity
Cytotoxicity

ABSTRACT

Introduction: *Acacia nilotica* is a valuable plant with medicinal properties that increasingly incites the curiosity of many researchers. Its pharmacological properties are reported in many studies, but the fact remains that the plant can be just as toxic as any modern pharmaceutical drug. It is very important to dispose sufficient knowledge on what are reported concerning its toxicity profile. This review is aimed to provide comprehensive summary (all-in-one) of what have been reported about the toxicity of *A. nilotica* and to determine the necessity or not to conduct more toxicological studies in a further step toward rationalizing its medicinal use.

Methods: Scientific information about the toxicity and or safety of *A. nilotica* reported elsewhere were reviewed. Search engines such as Google, Bing and Baidu and databases of scientific journals such as PubMed, Scopus, CAS, CABI, HINARI and AJOL were used to retrieve studies from 1999 to 2017.

Results: Few studies have reported the toxicity potential of *A. nilotica* and most with very limited information. Three of them have reported serious deleterious toxic effects of certain parts of the plant on major organ systems such as kidney and liver. Stem bark as part of *A. nilotica* appeared to be the most cited to cause observable clinical signs of toxicity and organs lesions.

Conclusion: Overall, this review provided comprehensive information on what is known about the toxicity of *A. nilotica* and showed the necessity to conduct more advanced long-term-based toxicological studies.

Implication for health policy/practice/research/medical education:

About 80% of the population from least developed countries rely on medicinal plant remedies such as that of *Acacia nilotica* for their primary health care needs. This situation has given rise to inquietude among health professionals and consumers on the issue of safety. Many scientific research data and or reviews published elsewhere highlighted the therapeutic potentials as well as inherent toxicity concerns associated with the use of *Acacia nilotica*. The present systematic review provided a comprehensive knowledge and critical analysis about all what is known concerning the safety of *Acacia nilotica* which are of relevance to most health professionals such as the clinician, pharmacist or toxicologist for decision making and or implementation.

Please cite this paper as: Manzo LM, Moussa I, Ikhiri K, Yu L. Toxicity studies of *Acacia nilotica* (L.): A review of the published scientific literature. J Herbm Pharmaco. 2019;8(3):163-172. doi: 10.15171/jhp.2019.26.

Introduction

The use of plants for the treatment of diseases dates back to the history of human life. In all parts of the world and more precisely in Africa and other least developed countries from Asia, plants are used in traditional medicine to treat different communicable and non-communicable diseases (1–3). It is estimated that more than 80% of people living in developing countries frequently use traditional practices for their primary health care needs (1,4). This situation has given rise to inquietude among health professionals

and consumers on the issue of safety. Indeed, many plants investigated elsewhere were found to contain toxic substances (5) like certain secondary metabolites. Among them are tannins, saponins, terpenoid, cyanogenic, toxic amino acids, glycosides, alkaloids, coumarins, flavonoids (6–8). Other factors such as the quantity consumed, the time of exposure, different parts of the plant, and genetic differences within the species may also cause certain side effects (9,10). Diarrhea, weight loss, agitation, convulsions, tremors, dyspnea, and mortality are the most

*Corresponding author: Lawaly Maman Manzo,
Email: manzolawal@yahoo.com

indicative clinical signs of toxicity. Life-threatening effects of certain toxins on organ systems such as liver, kidney, heart, spleen, brain, testicles, etc were also reported in many toxicological studies. Therefore, in the present study, toxicological studies related to *Acacia nilotica* (L.), a tree belonging to the family Mimosaceae were reviewed.

The species is native of Egypt and is widely distributed in various tropical and sub-tropical countries around the world. In Niger, the plant is frequently found in clay-sandy sites flooded by ponds where it flowers in the rainy season. It is common in the Delta and Senegal valley (11). The tree is 5 to 20 m (in humid zone) in high with a spherical crown. The stems and branches are usually black, cracked bark, gray-pink, exuding a reddish gum of low quality but which is edible, and is used in confectionery making. The tree has fine gray spines in axillary pairs (usually 3 to 12), 5 to 7.5 cm long in young trees. Mature trees are often thorn less. The leaves are bi-pinnate, with 3-6 pairs of pinnacles and 10-30 pairs of leaflets each, rachis with a gland at the bottom of the last pair of pinnae. Flowers with globular head of 1.2 to 1.5 cm in diameter with a bright golden yellow color, present on pedicels of 2-3 cm long are located at the ends of the branches. The pods are strongly constricted, white-gray, thick and soft (12).

Different parts of *A. nilotica* are widely used in traditional medicine for the treatment of various ailments. In different countries of the West Africa, *A. nilotica* pods, bark, gum, root, flowers and leaves are very solicited for the treatment of several diseases, such as gastrointestinal disorders (diarrhea, dysentery, hemorrhoid, abdominal aches, toothaches, sore throat, etc), diabetes, asthma, hypertension, etc (11,13).

Acacia nilotica is very rich in secondary metabolites (14). It contains a variety of bioactive components, such as gallic acid, ellagic acid, isoquercetin, leucocyanidin, kaempferol-7-diglucoside, naringenin-7-O- β -D-(6-O-galloyl) glucopyranoside, rutin, apigenin-6,8-bis-C-glucopyranoside, m-catechol and their derivatives, as well as galloylated derivatives of (+)-catechin and (+)-gallocatechin (15-17). The seeds are very rich in phenolic constituents and also proteins. The fruits are reported to be very rich in saponins and tannins (18). The leaves contain apigenin, 6-8-bis-D-glucoside, etc. The relative proportion of tannin in different parts of the plant is 50%, 7.6%, 13.5% for fruits, leaves and bark, respectively. The bark is rich in tannins (12-20%), terpenoids, saponins, etc. Its total extract is very rich in phenol. The root contains octacosanol, betulin, etc. Ahmadu et al reported the extraction, purification and identification of two new compounds [ethylgalate and (+)-catechin] from the bark of *A. nilotica* in a study conducted in Nigeria with the collaboration of CNRS of France (19).

Acacia nilotica has been used since time immemorial for its multiple pharmacological properties. The antibacterial potential of different plant parts has been reported by

several investigators (20-24). Anti-platelet activity of the plant extract was reported (25). A study conducted by Kalaivani et al showed that the plant is potentially rich in antioxidant substances. The standardization and or formulation of these various components as supplements will enhance the therapy of several diseases such as cancer, diabetes and other inflammatory diseases (26). Tahir et al reported ethyl acetate extracts to have a higher activity on *Plasmodium falciparum* (27). Jigam et al reported total methanol extract of the roots of *A. nilotica* to be significantly active against *Plasmodium berghei* (28).

Although the traditional use of different parts of *A. nilotica* is widespread by maceration, decoction or infusion, there is lack of systematic review that comprehensively reports all about what is known about its level of safety. Thus, the objective of this study was to review and evaluate the existing scientific information on the toxicity of *A. nilotica* (L.) by bibliographic literature review.

Materials and Methods

The literature review and search strategies were designed to provide an overview of the scientific information about the toxicity profile of *A. nilotica*. The relevant information were collected from different scientific studies. A blind search using Web search engines such as Google, Bing and Baidu and other databases of scientific journals such as PubMed (<https://www.ncbi.nlm.nih.gov/pubmed>), Scopus (<https://www.scopus.com>), CAS (<https://www.cas.org>), CABI (<https://www.cabi.org>), HINARI (<http://www.who.int/hinari/en/>) and AJOL (<https://www.ajol.info>) were used to retrieve valuable publications from 1999 to 2017. Keywords such as 'Acacia', '*Acacia nilotica*', 'toxic *Acacia nilotica*', '*Acacia nilotica* toxicity', 'medicinal plant toxicity' and 'toxicity' were used to collect relevant articles. University library (China Pharmaceutical University Library) and local or international institutions (e.g. IRD, CCFN, INRAN, LASDEL, and ENSP) present in Niger republic were also visited to include books, thesis and other scientific write-up with known academic rating. Criteria were set to screen the search results for relevance in the study. Only scientific journals published in English or French that reported toxicities effects of *A. nilotica* were considered. All information on toxicities of *A. nilotica* were extracted from the exploited literature.

Results

A total of 29 valuable studies out of 75 initially identified through database searching were included in this review. Criteria for study inclusion such as data accessibility, consistency, reliability, uniformity, well precised objectives, etc have permitted to exclude 47 (38.6%) studies. Toxicological study of medicinal plants is conducted *in vitro* or *in vivo*. Toxicity of a plant is appreciated on the basis of certain parameters or characteristics such as the

parts of plant used, the type of extract, the concentration of the extract, the mode of administration, the organism under consideration, and the LD₅₀ value expected to cause death in 50% in the treated animals in a given period (29,30). In addition, histological or genetic modifications are among the most relevant indicators for chronic or sub-chronic toxicity studies.

Information on toxicity or safety of *A. nilotica* reported by different studies are presented in Table 1. Of the 29 studies, 14 (48.3%) have reported the toxicity potential of *A. nilotica* with 7 (50.0%) reporting chronic injuries to organ systems and 7 (50.0%) reporting cytotoxic effects. Of the three parts (stem bark, root, fruits) of *A. nilotica* that have been reported in 7 different studies to cause organ systems injury, stem bark was found cited by up to 3 (42.8%) studies followed by root and fruits each cited by 2 studies. For the plant parts extraction, 14 (50.0%) studies have reported the use of water (aqueous) as the only extractor, 12 (42.8%) studies reported the use of either organic solvents (ethanol, methanol, hexane, acetone, n-butanl, ethyl acetate, and petroleum ether), and 2 (7.1%) studies accounting for parts identified not been extracted by any solvent. Methods used to evaluate the safety of *A. nilotica* included *in vivo* acute (AT) and sub-acute toxicity (SAT) tests and *in vitro* cytotoxicity tests. Took together, 15 (51.7%) studies have reported the use of *in vivo* acute toxicity as the only model for evaluation, while 7 (24.1%) reported the use of both *in vivo* acute and SAT assays, 6 (20.7%) reported the use of *in vitro* cytotoxicity assays and 1 (3.4%) study for both *in vitro* and *in vivo* acute toxicity assay. The mammalian and non-mammalian *in vivo* animals such as rats, mice, got, cat, and brine shrimp and the *in vitro* animal cell lines such as lymphocytes, erythrocytes, HepG2, Caco-2, and HeLa were used as experimental models. The route of extract and row plant administration in experimental animals included oral, intraperitoneal, intravenous, and intramuscular. Oral route alone was found as the most privileged option for acute cytotoxicity studies followed by intraperitoneal option for SAT studies.

Complex active ingredients present in most important plants were reported to cause varying degrees of side effects (31). Details on the studies that reported both indicative clinical signs, organ systems, and cell toxicity potential of *A. nilotica* are exhaustively reviewed.

Indicative clinical signs of toxicity

Administration of any toxic substances may lead to the development of early (1-2 hours for immediate release) or late (4-8 hours in sustained release) observable clinical signs alterations in the exposed living animals. Indicative observations of toxicity include tremors, convulsions, salivation, diarrhea, lethargy, sleep, coma, and mortality (58). Most of these signs of discomfort and disease appears when external circumstances or internal conditions due

to toxic substances cannot be adjusted by normal body mechanisms. A single change in any one system may result in numerous effects in other systems and thus clinical signs of disease are often quite similar for different diseases (Figure 1).

Plants are reported to content diverse secondary metabolites that can be toxic to body systems when took without cautious (1,5). Several studies have reported the contribution of certain medicinal plants in the development of various observable side effects after administration. Mohammed et al reported acute behavioral changes such as slight decrease of alertness and locomotion (at half an hour post treatment), slight animals' spontaneous activity (at 1 and 2 hours post treatment), and a slight rise in passivity (evident at 2 hours) during the first 24 hours post treatment of rats with fruits ethanol extract of *A. nilotica* at lower doses. At last, on day 21 all the earlier noted behavioral changes disappeared. In contrast, 20-100% mortality was reported in rats treated acutely with 50-500 mg/kg of extract on intraperitoneal administration (35). The methanol seeds extract of *A. nilotica* was investigated for acute toxicity in mice at doses of 50, 100, 200, 500, 1000 mg/kg body weight by Munira et al. The results showed little behavioral changes such as locomotor ataxia, diarrhea and weight loss (53). In 2015, Tanko et al reported a decrease in locomotion, a decrease in sensitivity to touch, and prostration as clinical signs of toxicity of the leaves extract of *A. nilotica* in rats after 12-18 hours post treatment (48). Also, in march 2015, in another study, the same author reported the same major observable clinical signs in rats that are treated with ethyl acetate and n-Butanol extracts of leaves of *A. nilotica* for 14 days with early deaths recorded after 12 hours and late deaths 48 hours after fractions administration (46). Umaru et al reported clinical signs of toxicity in rats treated with the aqueous pod extract of *A. nilotica*. Depression, anorexia and dyspnea indicative of respiratory and nervous-impairment were the altered clinical signs reported due to the treatment (42). Medani et al, on the other hand reported clinical signs of toxicity such as salivation, staggered gait, intermittent loss of voice, low appetite and death (between day 4 and day 8 at dose of 5 g/kg/d) in Nubian goats fed with whole pods of *A. nilotica* at doses of 1 to 5 g/kg/day for 35 days (47). Weight loss can be intentional, or unintentional and be a manifestation of illness due to the exposure to certain toxic substances (59,60). Different parts of *A. nilotica* were reported to significantly contribute to loss of appetite and thus decrease in body weight gain in the exposed animals. This was suggested to happen due to high tannin levels content in most parts of the plants (14,18,55). Al-Mustafa and Dafallah investigated the potential toxicity of aqueous pod extract of *A. nilotica* in rats maintained on 2% and 8% acacia diet for 2 and 4 weeks. The study showed a significantly decrease in weight gain in treated animals

Table 1. Results of literature search: *Acacia nilotica* parts and their toxicities

Plant part	Plant extract	Models	Length of the study	Experimentation	Route of administration	Main adverse effects	Ref.
Stem Bark	Aqueous	Mice	28 days	<i>In vivo</i> AT	Oral	Decreased levels of platelets; increase in levels of γ -glutamyl transpeptidase, Creatine kinase, and Total bilirubin; no mortality	(32)
					Intraperitoneal	Reduced body weight gain; no significant histopathological lesion on the liver, brain, kidney, lung, spleen, heart no mortality	
Fruits	Aqueous	Rats	35 days	<i>In vivo</i> AT-SAT	Oral	No significant modifications in the haematological values, makers of renal and hepatic functions, body weight, absolute and relative organ weights, structures of kidney and liver	(33)
Seeds	Methanol	Lymphocyte		<i>In vitro</i>		Low inhibition of lymphocyte proliferation	(27)
Seeds	Aqueous	Mice		<i>In vivo</i> AT	Intraperitoneal	Occasional abdominal cramping	(34)
		Cats	Intravenous				
Fruits	Ethanol	Rats	21 days	<i>In vivo</i> AT-SAT	Oral Intraperitoneal	Slight to moderate sedation on days 7 and 14; no behavioral changes were recorded on day 21; induced significant elevation in urea and ALT on day 21	(35)
Pods	Methanol	Rats	35 days	<i>In vivo</i> AT	Oral	No mortality was observed and no toxic reactions were observed	(36)
Root bark	Aqueous; ethanol	Rats	35 days	<i>In vivo</i> AT	Intraperitoneal	No lethality at the doses used	(37)
Pods		Goats	90 days	<i>In vivo</i> AT	Oral	The metabolic status of the animal not affected	(38)
Fruits	Aqueous	Caco-2		<i>In vitro</i>	Oral	Absence of significant cytotoxicity	(39)
		Rats	14 days	<i>In vivo</i> AT		No abnormal behavior and no mortality during the treatment	
Stem	Methanol	HepG2 HeLa		<i>In vitro</i>		Effects on mitochondrial activity, cellular proliferation and damage to cellular membrane	(10)
Leaves	Methanol	Rats	14 days	<i>In vivo</i> AT	Oral	No mortality in the treated groups; biochemical changes in the serum did not show any signs of toxicity	(40)
Root	Aqueous	Rats	28 days	<i>In vivo</i> AT	Oral	The extract did not cause death or change in physical appearance and morphological characteristics in the treated animals; no significant alteration of the hematological parameters	(41)
Pods	Aqueous	Rats	21 days	<i>In vivo</i> AT	Oral	No death in the treated groups; no significant alteration of the levels of red blood cells, hemoglobin concentration and packed cell volume; increase in body weight was observed in day 21	(42)
Leaves	Aqueous	Rats and human erythrocytes		<i>In vitro</i>		None of the extracts possessed any hemolytic activity against rat or human erythrocytes	(26)
Root	Organic	Human erythrocytes		<i>In vitro</i>		None of the extracts possessed any hemolytic activity against human erythrocytes	(43)
Leaves	Aqueous	Human erythrocytes		<i>In vitro</i>		At dose 200 μ g/mL produces highest hemolytic activity (8.9 \pm 0.16)	(44)

Table 1. Continued

Plant part	Plant extract	Models	Length of the study	Experimentation	Route of administration	Main adverse effects	Ref.
Stem bark	Methanol	Mice	14 days	<i>In vivo</i> AT	Intraperitoneal	25% mortality at 1600 mg/kg body weight and 50% mortality at 2000 mg/kg body weight	(45)
Leaves	Aqueous	Tats	14 days	<i>In vivo</i> AT	Oral	Decrease locomotor activity; decrease in sensitivity to touch; decrease in feed intake, and prostration; no significant change in the hematological parameters, serum urea, creatinine and potassium;	(46)
Pods		Goats	35 days	<i>In vivo</i> AT-SAT	Oral	Clinical signs such as salivation, staggered gait, intermittent loss of voice and low appetite were observed; histopathological testing revealed the presence of hepatic centrolobular necrosis lesions and fatty changes associated with the significant changes in GGT and ALP were indicating hepatic dysfunction; renal malfunction is indicated by hemorrhages in addition to the change in urea concentration	(47)
Leaves	Ethyl acetate; n-Butanol	Rats	14 days	<i>In vivo</i> AT	Intraperitoneal	Decreased locomotor activity and sensitivity to touch and pain; no significant alteration of the hematological values; significantly increase in urea level, potassium and chloride ions; no mortality was recorded	(48)
Aerial parts	Methanol	Rats	14 days	<i>In vivo</i> AT	Oral	No deaths or adverse effects were detected during the 24-hour observation period in rat treated with up to 3000 mg/kg bw	(49)
Stem Bark	Aqueous	Mice	28 days	<i>In vivo</i> AT-SAT	Oral	Lowered blood glucose levels in a dose dependent manner; significant low rate of weekly weight gain; significantly decreased red cell distribution width; significantly decreased GGT and α -AMYL; no major histopathological changes in the organs examined	(50)
					Intraperitoneal	Significant loss of body weight; no significant change in the hematological parameters; no significant changes for most enzymes except a decline in ALP; no major histopathological changes in the organs examined that is liver, heart, kidney, lungs, brain, testis, intestines and spleen	
Root	Methanol	Mice	35 days	<i>In vivo</i> AT-SAT	Oral	Significant decreases in whole body weight and Packed Cell Volume; elevated Serum triglycerides, Glutamate Pyruvate Transaminase, Glutamate Oxaloacetate Transaminase and Chloride; histopathological examinations indicated no changes in cardiac, pancreatic, spleen and intestinal tissues; feathery degeneration of hepatocytes and destruction of nephrons were observed	(51)
Root	Aqueous	Mice	14 days	<i>In vivo</i> AT	Oral	No mortality; significant reduction in the activity of lactate dehydrogenase was observed at 250 and 500 mg/kg b.w; significant increase in alanine aminotransferase, aspartate aminotransferase and ALP activities	(52)
		Rats	28 days	<i>In vivo</i> SAT			
Seeds	Methanol	Mice		<i>In vivo</i> AT	Oral	No mortality in mice during 48 h observation; little behavioral changes, locomotor ataxia, diarrhea and weight loss were observed; food and water intake had no significant difference among the group	(53)
Pods	Aqueous	Rats	14 days	<i>In vivo</i> AT	Oral	No mortality at a limit dose of 3000 mg/kg body weight	(54)
Pods	Aqueous	Rats	28 days	<i>In vivo</i> AT-SAT	Oral	Significant reduction in body weight; no significant changes in serum parameters of hepatic and renal functions, fasting glucose and triglycerides were observed; no mortality and no significant histopathological changes in liver sections were noted	(55)
Leaves	Aqueous	Rats	28 days	<i>In vivo</i> AT	Oral	No apparent toxicity was observed in rats treated orally with increasing doses	(56)
					Intramuscular	Claustration was observed	
Stem Bark	Organic	Brine shrimp larvae		<i>In vitro</i>		Moderate toxicity	(57)

AT: acute toxicity; SAT: sub-acute toxicity; GGT: γ -Glutamyl Transferase; ALP: Alkaline Phosphatase; α -AMYL: α -Amylase.

suggesting the presence of growth impairing substances such as tannin in acacia pods (55). In another study, Mohan et al, also reported a decrease in body weight in rats fed with 2% and 8% leaves aqueous extract of *A. nilotica* in the diet for 2 and 4 weeks (40). While on the other hand, the methanol root extract of *A. nilotica* was reported by Jigam et al to significantly contribute to decrease in the body weight of mice treated over a 5 week period (51).

Kidney and liver injury

Animal exposure to toxic substances can impair a particular organ or organs function in many ways. Like modern pharmaceutical medicines, medicinal plants were also reported to have the potential to cause organ injury. Possible reasons of such toxic effects are diverse, including the use of inherently toxic medicinal plants, improper intake (over dosage or longer than required duration of use) of plants, drug-plant medicine interactions, and contamination by toxic heavy metals (31) (Figure 1).

Fortunately, the body has mechanisms, mainly via certain key organs, to process and eliminate many of these substances. The functions of these organs are so vast and very indispensable that they alone, are testaments to the ingenuity of the body. Failure to remove toxins from the body system organs can lead to nephrotoxicity (61), hepatotoxicity (62) and more. Many research studies around the world have demonstrated and reported the implication of certain medicinal plants in the development of kidney, liver, heart, lungs, spleen, intestines, brain and testicles injury *in vivo* (62–70). Very few studies have reported the toxic effects of different parts of *A. nilotica* in different organs of animal models such as rat, goat, and mice. Medani et al reported the administration of the aqueous pod extracts of *A. nilotica* at doses of 1 and 5 g/kg body weight to Nubian goats dispatched in two groups for 35 days. Clinical signs and changes in hematological and histology were reported. The histopathological testing revealed the presence of hepatic centrilobular necrosis lesions and fatty changes associated with the significant changes in γ -glutamyl transferase (GGT) and alkaline phosphatase (ALP) were indicating hepatic dysfunction;

renal malfunction was indicated by hemorrhages in addition to the change in urea concentration (47). Alli et al studied the toxicological effects of a single dose (acute) and of repeated doses (sub-acute) of aqueous root extract of *A. nilotica* in rodents. In the acute toxicity test, Swiss albino mice were orally administered aqueous extract of *A. nilotica* at doses 50, 300 and 2000 mg/kg body weight for 14 days. In the SAT study, rats received 125, 250 and 500 mg/kg b.w of the extract for 28 days by oral gavage. Changes in clinical signs, hematological and biochemical parameters and histology were recorded. Increased level of alanine aminotransferase, aspartate aminotransferase and ALP activities were recorded at 500 mg/kg b.w. Single dose administration of the aqueous extract in mice was found safe at doses higher than 250 mg/kg b.w., while repeated administration of doses higher than 250 mg/kg b.w of the extract for 28 days in rats caused hepatotoxicity. Renal function parameters analyzed at any of the doses of the extract administered were found unaltered. This implies that the extract does not have adverse effects on renal function at the doses tested (52). Juma et al in another study reported the effects of *A. nilotica* on enzyme and non-enzyme makers of liver and kidney injury. In this study, the aqueous stem bark extract of *A. nilotica* at 50, 100, 200, and 300 mg/kg body weight were orally and intraperitoneally administered to male Swiss white albino mice daily for 28 days. Changes in body and organ weight, hematological and biochemical parameters and histology were recorded. Intraperitoneal administration of the extract at 1 g/kg body weight significantly reduced body weight gain, percent organ to body weight of testes, while oral administration at the same dose decreased levels of platelets. Oral administration of the extract at 1 g/kg b.w. has led to the development of certain abnormalities in the levels of γ -glutamyltransferase, creatine kinase, alanine aminotransferase, aspartate aminotransferase, α -amylase, ALP and total bilirubin. These conditions may explain the hepatotoxic, cardiovascular toxicity, and nephrotoxic effects of *A. nilotica* extract on biomarkers of liver, heart, and kidney function. The histopathological study carried out on formalin fixed kidney tissue extracted from a

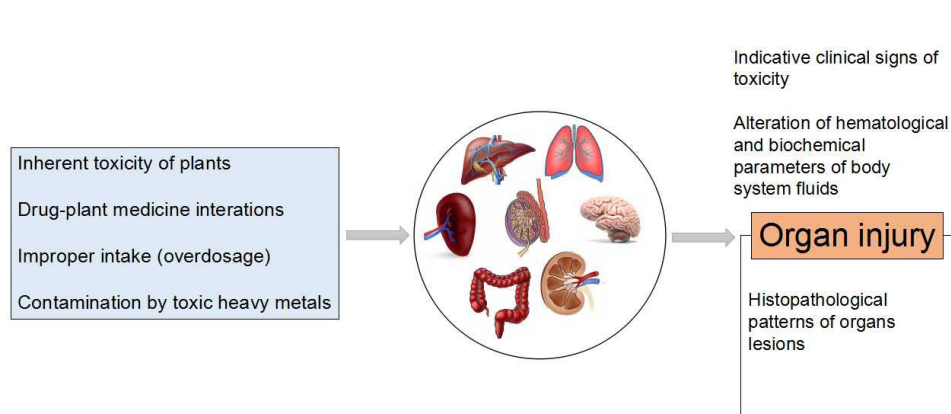


Figure 1. Possible reasons for organ injury as a result of medicinal plant intake.

sacrificed treated mice indicated that long term exposure to doses of aqueous extract of *A. nilotica* had no obvious histopathological lesions on the liver, kidney, and other organs (32). In a thesis research study, Mwangi evaluated six plants including *A. nilotica* for their toxicity using aqueous stem bark extracts in mice treated with a doses of 1000 mg/kg b.w. orally for 28 days. Significant increase in the level of uric acid, an important marker of kidney function, was recorded. The intraperitoneal administration of the extract indicated an increase in kidney weight as compared to normal control mice. Histopathological observations of kidney, liver, heart, and other organs extracted from sacrificed treated mice for 28 days showed normal cellular architecture, indicating that the extracts were not toxic to the organs at the dosage level used (50). Jigam et al investigated the toxicity potential of the crude methanol root extract of *A. nilotica* in mice gavaged with 300 mg/kg body weight for 35 days. The results indicated significant elevation in oxaloacetate transaminase and Chloride. Histopathological examinations indicated a feathery degeneration of hepatocytes and destruction of nephrons (51). Mohammed et al investigated the toxicity potential of the ethanol fruit extract of *A. nilotica* in rats treated at doses of 75, 100, 112.5, 125, 187.5, 250 and 500 mg/kg for 21 days. Nephrotoxicity and hepatotoxicity assessments were based on elevated urea, creatinine, ALT (GPT) and AST (GOT) in plasma. On day 21 no behavioral changes were recorded. However, a treatment for three weeks induced significant elevation in urea and ALT. The increase in the level of both biomarkers (urea and ALT) suggested that kidney and liver functions are respectively impaired in the treated rats, particularly at high dose (35).

Cytotoxicity effect

Several *in vitro* assays involving different types of mammalian cells have been used for high-throughput screening of toxicity effects of potential medicinal compounds as well as to identify potential safety (39,71). Certain chemical constituents of medicinal plants are found to have a hemolytic or anti-hemolytic effect on animal erythrocytes (44,72,73). Few number of studies conducted elsewhere have reported erythrocyte toxicity caused by different plant extracts of *A. nilotica*. Sulaiman and Gopalakrishnan studied the hemolytic activity of the aqueous extracts of different *Acacia* species including *A. nilotica* at doses of 50 µg/mL, 100 µg/mL, 150 µg/mL and 200 µg/mL. *A. nilotica* (at dose 200 µg/mL) possesses highest hemolytic activity (8.9 ± 0.16). Hemolytic percentage was found to be increasing with increase in dose (44). In another study, Kalaivani et al reported the *in vitro* cytotoxicity effect of the aqueous leaves extracts of *A. nilotica* at different doses (5-500 µg/mL) against rat and human erythrocytes. The test aqueous leaves extracts showed hemolytic effect with an $IC_{50} < 200$ µg/mL

(26). While Rasool et al reported the hemolytic effect of either organic (Chloroform, ethyl acetate, ethanol, and methanol) root extracts of *A. nilotica*. The percentage lysis of the erythrocytes by plant extracts was found to be in the range of 1.27-3.59% (43). Tahir et al used human peripheral blood mononuclear cells (PBMC) to evaluate the toxicity effect of aqueous and organic extracts of *A. nilotica in vitro* (27). The methanol extracts of seed and husk showed low toxicity effects to the tested human lymphocyte at 100 µg/mL. Dikti Vildina et al used Caco-2 cell lines as model to evaluate the cytotoxicity effect of fruit extracts of *A. nilotica* (increasing concentrations up to 100 or 150 µg/mL) prior to *in vivo* toxicological studies (39). The results demonstrated that the viability of the tested human intestinal Caco-2 cells is inhibited by the crude extract of *A. nilotica* (mean CC_{50} 93.2 ± 1.1 µg/mL (µM)). van den Bout-van den Beukel et al evaluated the effects of stem extracts of *A. nilotica* at doses of 8 to 500 µg/mL on mitochondrial activity, cellular proliferation, damage to the cellular membrane, glutathione depletion and the electron transport chain activity with the aid of Alamar Blue, Hoechst 33342, calcein-AM uptake, glutathione depletion and O₂-consumption assays, respectively. Hep-G2 and HeLa human cell lines were used as models. On the basis of the results obtained from these five assays, the plant was found to be highly toxic (10). Adoum used the brine shrimp *in vitro* lethality bioassay to predict the cytotoxic effect of the organic stem bark extract of *A. nilotica*. The results demonstrated moderate toxicity of the plant extract on brine shrimps (57).

Conclusion

Are there sufficient knowledge available to justify the safety of *A. nilotica*? This inquietude is the key goal of this review. Several ethnobotanical and ethnopharmacological studies conducted around the developing world have emphasized on the importance of *A. nilotica* in most indigenous communities to treat different diseases. From most of these surveys, it follows that local communities especially women have used *A. nilotica* for generations without any reports of pathologic effects (56). However, the increasing demands in the use of *A. nilotica* as alternative agent to treat various diseases have incited the curiosity of numerous scientists to further investigate its potentials. Found to be very rich in secondary metabolites and sufficiently active, scientists have hypothesized on its probable potentials to cause toxicity and though pursued several studies for justification. In general, chemical compounds present in the plant at certain doses could cause damage to the body systems; thereby the higher the dose administered the more the injuries caused are important especially if the consumption is regular. It has been noted that studies reporting the toxicity potential of *A. nilotica* are very few, most with very limited information and corresponding to short-term period of less than 15 days. Of the studies that

are reviewed in this paper, only 3 have reported serious deleterious toxic effects of certain parts of *A. nilotica* on major organ systems such as liver and kidney. Alterations in certain hematological and biochemical parameters in relation to organs injuries but with no histopathological lesions were also reported by other 4 studies. All of these anomalies were observed after long-term exposure and at relatively higher doses. Stem bark as part of *A. nilotica* appeared to be the most cited to cause observable clinical signs of toxicity and organs lesions.

Overall, because of the remarkable increasing demand that the therapeutic usage of different parts of *A. nilotica* has attend, as well as its enormous potential in the near future, more advanced long-term-based toxicological studies are clearly needed.

Authors' contributions

All the authors contributed to data collection and preparation of the manuscript. The first draft was prepared by Lawaly Maman Manzo. All authors read the final version and confirmed for the publication.

Conflict of interests

Authors declare there is not any conflict of interest.

Ethical considerations

Ethical issues regarding data acquisition, review and analysis have been carefully observed by authors.

Funding/Support

Supported by the UNESCO/People's Republic of China (The Great Wall) Co-sponsored Fellowships Programme.

References

- Boukandou Mounanga M, Mewono L, Aboughe Angone S. Toxicity studies of medicinal plants used in sub-Saharan Africa. *J Ethnopharmacol.* 2015;174:618-27. doi: 10.1016/j.jep.2015.06.005.
- Diallo D, Paulsen BS, Liljeback TH, Michaelsen TE. The malian medicinal plant *Trichilia emetica*; studies on polysaccharides with complement fixing ability. *J Ethnopharmacol.* 2003;84(2-3):279-87.
- Gurib-Fakim A. Medicinal plants: traditions of yesterday and drugs of tomorrow. *Mol Aspects Med.* 2006;27(1):1-93. doi: 10.1016/j.mam.2005.07.008.
- van Dyk S, Griffiths S, van Zyl RL, Malan SF. The importance of including toxicity assays when screening plant extracts for antimalarial activity. *Afr J Biotechnol.* 2009;8(20):5595-601. doi: 10.4314/ajb.v8i20.66014.
- Ishii R, Yoshikawa K, Minakata H, Komura H, Kada T. Specificities of bio-antimutagens in plant kingdom. *Agric Biol Chem.* 1984;48(10):2587-91. doi: 10.1080/00021369.1984.10866552.
- Ibegbulem CO, Chikezie PC, Mbagwu FN. Medicinal potentials and toxicity concerns of bioactive principles. *Med Aromat Plants.* 2015;4(3):202. doi: 10.4172/2167-0412.1000202.
- Dai J, Mumper RJ. Plant phenolics: extraction, analysis and their antioxidant and anticancer properties. *Molecules.* 2010;15(10):7313-52. doi: 10.3390/molecules15107313.
- Demain AL, Fang A. The natural functions of secondary metabolites. *Adv Biochem Eng Biotechnol.* 2000;69:1-39.
- Nasri H, Shirzad H. Toxicity and safety of medicinal plants. *J Herbmmed Pharmacol.* 2013;2(2):21-2.
- van den Bout-van den Beukel CJ, Hamza OJ, Moshi MJ, Matee MI, Mikx F, Burger DM, et al. Evaluation of cytotoxic, genotoxic and CYP450 enzymatic competition effects of Tanzanian plant extracts traditionally used for treatment of fungal infections. *Basic Clin Pharmacol Toxicol.* 2008;102(6):515-26. doi: 10.1111/j.1742-7843.2008.00225.x.
- Raphael D, Eklun-Natey, Annie B. *Pharmacopée Africaine: Dictionnaire et Monographies multilingues du potentiel medicinal des plantes Africaines, Afrique de l'Ouest.* Geneve: Traditions et Médecine T & M, 2012.
- New TR. *A biology of acacias.* Oxford University Press; 1984. p. 153.
- Koube J, Dongmo SS, Guiama VD, Bum EN. Ethnomedicinal survey of Gavadé (*Acacia nilotica*): a medicinal plant used in sahelian zone of Cameroon, Central Africa. *Int J Innov Appl Stud.* 2016;16(4):820-7.
- Sotohy SA, Sayed AN, Ahmed MM. Effect of tannin-rich plant (*Acacia nilotica*) on some nutritional and bacteriological parameters in goats. *Dtsch Tierarztl Wochenschr.* 1997;104(10):432-5.
- Maldini M, Montoro P, Hamed AI, Mahalel UA, Oleszek W, Stochmal A, et al. Strong antioxidant phenolics from *Acacia nilotica*: Profiling by ESI-MS and qualitative-quantitative determination by LC-ESI-MS. *J Pharm Biomed Anal.* 2011;56(2):228-39. doi: 10.1016/j.jpba.2011.05.019.
- Singh R, Singh B, Singh S, Kumar N, Kumar S, Arora S. Anti-free radical activities of kaempferol isolated from *Acacia nilotica* (L.) Willd. Ex. Del. *Toxicol In Vitro.* 2008;22(8):1965-70. doi: 10.1016/j.tiv.2008.08.007.
- Malan E. Derivatives of (+)-catechin-5-gallate from the bark of *Acacia nilotica*. *Phytochemistry.* 1991;30(8):2737-9. doi: 10.1016/0031-9422(91)85134-L.
- Manzo LM, Moussa I, Ikhiri K. Phytochemical screening of selected medicinal plants used against diarrhea in Niger, West Africa. *Int J Herb Med.* 2017;5(4):32-8.
- Ahmadu AA, Agunu A, Nguyen T, Baratte B, Foll-Josselin B, Ruchaud S, et al. Constituents of *Acacia nilotica* (L.) Delile with novel Kinase inhibitory activity. *Planta Medica International Open.* 2017;4(3):e108-13. doi: 10.1055/s-0043-122397.
- Deshpande SN, Kadam DG. Phytochemical analysis and antibacterial activity of *Acacia nilotica* against *Staphylococcus mutans*. *Int J Green Pharm.* 2016;5(1):104.
- Angelo RU. Efficacy of *Acacia nilotica* Extracts Towards Microbicidal Activity against Pathogens. *Int J Curr Microbiol Appl Sci.* 2015;4(10):33-42.
- Yohana GG, Tsega KG, Dawit TM, Negusse BG. Antimicrobial screening of the different parts of *Acacia nilotica* and *Comete abyssinica*. *Asian Journal of Phytomedicine and Clinical Research.* 2015;3(3):105-10.
- Auwal MS, Saka S, Mairiga IA, Sanda KA, Shuaibu A, Ibrahim A. Preliminary phytochemical and elemental

- analysis of aqueous and fractionated pod extracts of *Acacia nilotica* (Thorn mimosa). *Vet Res Forum*. 2014;5(2):95-100.
24. Khan ME, Hati SS, Abdu KB, Babale A, Achi MI. Chemical analysis and antibacterial activity of *Acacia nilotica* and *Tapinanthus dodoneifolius* growing in Nigeria. *Med Aromat Plant Sci Biotechnol*. 2008;2(2):128-30.
 25. Shah BH, Safdar B, Virani SS, Nawaz Z, Saeed SA, Gilani AH. The antiplatelet aggregatory activity of *Acacia nilotica* is due to blockade of calcium influx through membrane calcium channels. *Gen Pharmacol*. 1997;29(2):251-5.
 26. Kalaivani T, Rajasekaran C, Suthindhiran K, Mathew L. Free radical scavenging, cytotoxic and hemolytic activities from leaves of *Acacia nilotica* (L.) Wild. ex. *Delile* subsp. *indica* (Benth.) Brenan. *Evid Based Complement Alternat Med*. 2011;2011:274741. doi: 10.1093/ecam/nea060.
 27. El-Tahir A, Satti GM, Khalid SA. Antiplasmodial activity of selected sudanese medicinal plants with emphasis on *Acacia nilotica*. *Phytother Res*. 1999;13(6):474-8.
 28. Jigam AA, Akanya HO, Dauda BEN, Okogun JO. Polygalloyltannin isolated from the roots of *Acacia nilotica* Del.(Leguminosae) is effective against Plasmodium berghei in mice. *J Med Plant Res*. 2010;4(12):1169-75. doi: 10.5897/JMPR10.004.
 29. Rispin A, Farrar D, Margosches E, Gupta K, Stitzel K, Carr G, et al. Alternative methods for the median lethal dose (LD₅₀) test: the up-and-down procedure for acute oral toxicity. *ILAR J*. 2002;43(4):233-43.
 30. Walum E. Acute oral toxicity. *Environ Health Perspect*. 1998;106 Suppl 2:497-503. doi: 10.1289/ehp.98106497.
 31. Yang B, Xie Y, Guo M, Rosner MH, Yang H, Ronco C. Nephrotoxicity and Chinese Herbal Medicine. *Clin J Am Soc Nephrol*. 2018;13(10):1605-11. doi: 10.2215/cjn.11571017.
 32. Juma KK, Abdirahman YA, Gitahi SM, Agyirifo DS, Ngugi PM, Gathumbi PK, et al. The hypoglycemic activity and safety of aqueous stem bark extracts of *Acacia nilotica*. *J Drug Metab Toxicol*. 2015;6(4):189. doi: 10.4172/2157-7609.1000189.
 33. Koube J, Dongmo SS, Guiama VD, Doubla A, Vedekoi J, Goulime M, et al. Safety assessment of the fruit extract of *Acacia nilotica* Linn. Willd ex Delile using rat models. *Int J Biosci*. 2017;10(4):81-92. doi: 10.12692/ijb/10.4.81-92.
 34. Amos S, Akah PA, Odukwe CJ, Gamaniel KS, Wambede C. The pharmacological effects of an aqueous extract from *Acacia nilotica* seeds. *Phytother Res*. 1999;13(8):683-5.
 35. Mohammed EYG, Abdulhadi NH, Badico EEM, El-Hadiyah TM. Toxic potential of ethanolic extract of *Acacia nilotica* (Garad) in rats. *Sudan J Med Sci*. 2011;6(1):1-5. doi: 10.4314/sjms.v6i1.67269.
 36. Khan TA, Anjaria JK, Dedhia V, Gohel AK. Bioactivity guided fractionation and anti-inflammatory activity of *Acacia nilotica* pods. *Int J Pharm Pharm Sci*. 2015;7(7):380-3.
 37. Timothy SY, Mohd AS, Waziz CH, Milagawanda HH, Elon RI, Midala TA. Effects of aqueous and ethanol root bark extracts of *Acacia nilotica* on rabbit jejunum and castor oil induced diarrhea in rats. *Niger J Pharm Biomed Res*. 2017;2(1):46-50.
 38. Paswan JK, Kumar K, Kumar S, Chandramoni, Kumar A, Kumar D, et al. Effect of feeding *Acacia nilotica* pod meal on hematobiochemical profile and fecal egg count in goats. *Vet World*. 2016;9(12):1400-6. doi: 10.14202/vetworld.2016.1400-1406.
 39. Dikti Vildina J, Kalmobe J, Djafsia B, Schmidt TJ, Liebau E, Ndjonka D. Anti-Onchocerca and anti-Caenorhabditis activity of a hydro-alcoholic extract from the fruits of *Acacia nilotica* and some Proanthocyanidin derivatives. *Molecules*. 2017;22(5). doi: 10.3390/molecules22050748.
 40. Mohan S, Thiagarajan K, Chandrasekaran R, Arul J. In vitro protection of biological macromolecules against oxidative stress and in vivo toxicity evaluation of *Acacia nilotica* (L.) and ethyl gallate in rats. *BMC Complement Altern Med*. 2014;14:257. doi: 10.1186/1472-6882-14-257.
 41. Alli LA. Evaluation of root extract of *Acacia nilotica* on Haematological and lipid profile in rats. *European J Med Plants*. 2016;17(4):1-7. doi: 10.9734/EJMP/2016/31262.
 42. Umaru B, Saka S, Mahre MB, Ojo NA, Dogo HM, Onyeyili PA. Acute toxicity and effects of aqueous pod extract of *Acacia nilotica* on some haematological parameters and body weight in rats. *International Journal of Health and Medical Information*. 2015;4(3):37-42.
 43. Rasool N, Tehseen H, Riaz M, Rizwan K, Zubair M, Mahmood Y, et al. Cytotoxicity studies and antioxidant potential of *Acacia nilotica* roots. *Int J Chem Biochem Sci*. 2013;3:34-41.
 44. Sulaiman CT, Gopalakrishnan VK. Radical scavenging and in-vitro hemolytic activity of aqueous extracts of selected acacia species. *J Appl Pharm Sci*. 2013;3(3):109-11. doi: 10.7324/JAPS.2013.30321.
 45. Ogbadoyi EO, Garba MH, Kabiru AY, Mann A, Okogun JI. Therapeutic evaluation of *Acacia nilotica* (Lin) stem bark extract in experimental African trypanosomiasis. *Int J Appl Res Nat Prod*. 2011;4(2):11-8.
 46. Tanko Y, Ibrahim RA, Muhammad A, Eze Ejike D, Jimoh A, Mohammed KA, et al. Evaluation of the effect of crude extract and aqueous fraction of *Acacia nilotica* leaves on haematological indices and serum electrolytes levels on diabetic wistar rats. *J Adv Biol Biotechnol*. 2015;4(2):1-7. doi: 10.9734/JABB/2015/18350.
 47. Medani AB, Samia MAE, Ahmed EA. Toxicity of *Acacia nilotica* (Garad) to Nubian goats. *Open Access J Toxicol*. 2016;1(2):1-5.
 48. Tanko Y, Obafemi MF, Muhammad A, Eze Ejike D. Effects of ethylacetate and n-butanol fractions of *Acacia nilotica* extract on some haematological profile and serum electrolytes levels of alloxan-induced diabetic wistar rats. *European J Biotechnol Biosci*. 2015;3(3):31-4.
 49. Kannan N, Sakthivel KM, Guruvayoorappan C. Protective Effect of *Acacia nilotica* (L.) against acetaminophen-induced hepatocellular damage in wistar rats. *Adv Pharmacol Sci*. 2013;2013:987692. doi: 10.1155/2013/987692.
 50. Mwangi JM. Antidiabetic activity and safety of aloe volkensii, *Acacia nilotica*, *Euclaea divinorum*, *Rhoicissus tridentata*, *Cynanchum viminalis* and *Urtica dioica* in mice. Kenyatta University; 2015.
 51. Jigam AA, Muhammad HL, Adefolalu, FS, Abdulkadir A, Jimoh T. Effects of crude *Acacia nilotica* del. root extracts in mice. *Int J Appl Biol Res*. 2011;3(1):56-68.
 52. Alli LA, Adesokan AA, Salawu OA, Akanji MA. Toxicological studies of aqueous extract of *Acacia nilotica*

- root. *Interdiscip Toxicol.* 2015;8(1):48-54. doi: 10.1515/intox-2015-0005.
53. Munira S, Naim Z, Akter S, Majumber R, Kabir H, Alam B. Evaluation of analgesic, anti-inflammatory and CNS depression activities of the methanolic extract of *Acacia nilotica* seed. *European J Biol Sci.* 2013;5(4):123-30. doi: 10.5829/idosi.ejbs.2013.5.4.81143.
 54. Auwal MS, Saka S, Shuaibu A, Mairiga IA, Sanda KA, Ibrahim A, et al. Phytochemical properties and hypoglycemic activity of the aqueous and fractionated portions of *Acacia nilotica* (Fabaceae) pod extracts on blood glucose level in normoglycemic Wistar albino rats. *J Med Sci.* 2013;13(2):111-7. doi: 10.3923/jms.2013.111.117.
 55. Al-Mustafa ZH, Dafallah AA. A study on the toxicology of *Acacia nilotica*. *Am J Chin Med.* 2000;28(1):123-9. doi: 10.1142/s0192415x00000155.
 56. Lompo-Ouedraogo Z. Plants and lactation: from tradition to the mechanism of action. Wageningen Universiteit; 2003.
 57. Adoum OA. Determination of toxicity levels of some savannah plants using brine shrimp test (BST). *Bayero J Pure Appl Sci.* 2009;2(1):135-8. doi: 10.4314/bajopas.v2i1.58525.
 58. Parasuraman S. Toxicological screening. *J Pharmacol Pharmacother.* 2011;2(2):74-9. doi: 10.4103/0976-500x.81895.
 59. Teo SK, Stirling DI, Thomas SD, Evans MG, Khetani VD. A 90-day oral gavage toxicity study of d-methylphenidate and d,l-methylphenidate in beagle dogs. *Int J Toxicol.* 2003;22(3):215-26. doi: 10.1080/10915810305100.
 60. Raza M, Al-Shabanah OA, El-Hadiyah TM, Al-Majed AA. Effect of prolonged vigabatrin treatment on hematological and biochemical parameters in plasma, liver and kidney of Swiss albino mice. *Sci Pharm.* 2002;70(2):135-45. doi: 10.3797/scipharm.aut-02-16.
 61. Gillerot G, Jadoul M, Arlt VM, van Ypersele De Strihou C, Schmeiser HH, But PP, et al. Aristolochic acid nephropathy in a Chinese patient: time to abandon the term "Chinese herbs nephropathy"? *Am J Kidney Dis.* 2001;38(5):E26.
 62. Thompson M, Jaiswal Y, Wang I, Williams L. Hepatotoxicity: treatment, causes and applications of medicinal plants as therapeutic agents. *The Journal of Phytopharmacology.* 2017;6(3):186-93.
 63. Nauffal M, Gabardi S. Nephrotoxicity of natural products. *Blood Purif.* 2016;41(1-3):123-9. doi: 10.1159/000441268.
 64. Lord GM, Tagore R, Cook T, Gower P, Pusey CD. Nephropathy caused by Chinese herbs in the UK. *Lancet.* 1999;354(9177):481-2. doi: 10.1016/s0140-6736(99)03380-2.
 65. Akiyasu T, Paudyal B, Paudyal P, Kumiko M, Kazue U, Takuji N, et al. A case report of acute renal failure associated with bee pollen contained in nutritional supplements. *Ther Apher Dial.* 2010;14(1):93-7. doi: 10.1111/j.1744-9987.2009.00707.x.
 66. Li YJ, Lin JL, Yang CW, Yu CC. Acute renal failure induced by a Brazilian variety of propolis. *Am J Kidney Dis.* 2005;46(6):e125-9. doi: 10.1053/j.ajkd.2005.08.028.
 67. Vanherweghem LJ. Misuse of herbal remedies: the case of an outbreak of terminal renal failure in Belgium (Chinese herbs nephropathy). *J Altern Complement Med.* 1998;4(1):9-13. doi: 10.1089/acm.1998.4.1-9.
 68. Stournaras E, Tziomalos K. Herbal medicine-related hepatotoxicity. *World J Hepatol.* 2015;7(19):2189-93. doi: 10.4254/wjh.v7.i19.2189.
 69. Schoepfer AM, Engel A, Fattinger K, Marbet UA, Cribblez D, Reichen J, et al. Herbal does not mean innocuous: ten cases of severe hepatotoxicity associated with dietary supplements from Herbalife products. *J Hepatol.* 2007;47(4):521-6. doi: 10.1016/j.jhep.2007.06.014.
 70. Nadir A, Reddy D, Van Thiel DH. Cascara sagrada-induced intrahepatic cholestasis causing portal hypertension: case report and review of herbal hepatotoxicity. *Am J Gastroenterol.* 2000;95(12):3634-7. doi: 10.1111/j.1572-0241.2000.03386.x.
 71. Schoonen WG, Westerink WM, de Roos JA, Debiton E. Cytotoxic effects of 100 reference compounds on Hep G2 and HeLa cells and of 60 compounds on ECC-1 and CHO cells. I mechanistic assays on ROS, glutathione depletion and calcein uptake. *Toxicol In Vitro.* 2005;19(4):505-16. doi: 10.1016/j.tiv.2005.01.003.
 72. Bulmus V, Woodward M, Lin L, Murthy N, Stayton P, Hoffman A. A new pH-responsive and glutathione-reactive, endosomal membrane-disruptive polymeric carrier for intracellular delivery of biomolecular drugs. *J Control Release.* 2003;93(2):105-20.
 73. de Freitas MV, Netto Rde C, da Costa Huss JC, de Souza TM, Costa JO, Firmino CB, et al. Influence of aqueous crude extracts of medicinal plants on the osmotic stability of human erythrocytes. *Toxicol In Vitro.* 2008;22(1):219-24. doi: 10.1016/j.tiv.2007.07.010.