



# Protection efficiency of red radish seeds and roots against paracetamol mediated hepatotoxicity in rats

Doha A. Mohamed<sup>1</sup>, Rasha S. Mohamed<sup>1\*</sup>, Hend A. Essa<sup>1</sup>, Sherein S. Abdelgayed<sup>2</sup><sup>1</sup>Nutrition and Food Sciences Department, National Research Centre, Dokki, Cairo, Egypt<sup>2</sup>Pathology Department, Faculty of Veterinary Medicine, Cairo University, Cairo, Egypt

## ARTICLE INFO

**Article Type:**  
Original Article

**Article History:**  
Received: 31 March 2019  
Accepted: 10 July 2019

**Keywords:**  
Red radish  
Liver  
Paracetamol  
Hepatotoxicity

## ABSTRACT

**Introduction:** Protection of liver from the aggressive force of various environmental and chemical agents is very important for the overall health of an individual. So, the present study aimed to evaluate the protection efficiency of crude extracts of red radish seeds and roots against paracetamol mediated hepatotoxicity in rats.

**Methods:** Twenty-four male Wistar rats were divided into four groups. Group I was served as normal rats, Group II received orally single dose of 2 g paracetamol/kg body weight on the 22nd day, Group III and Group IV were administered orally with 300 mg/kg/d crude ethanol extract of either seeds or roots of red radish for 21 days, then received paracetamol on 22nd day. After 48 hours of paracetamol administration blood was withdrawn to determine the activities of aspartate transaminase (AST), alanine transaminase (ALT), alkaline phosphatase (ALP) and Gama-GT ( $\gamma$ -GT) as well as total and direct bilirubin. Also, liver tissues were separated to determine malondialdehyde (MDA) and nitric oxide (NO) as well as histological changes.

**Results:** Pretreatment of rats with crude ethanol extract of either seeds or roots of red radish significantly ( $P \leq 0.05$ ) suppressed the elevations in serum activities of ALT, AST, ALP,  $\gamma$ -GT, total and direct bilirubin as well as liver MDA and NO levels. The results of histopathologic examinations were consistent with the biochemical results.

**Conclusion:** Seeds and roots of red radish have a protection efficiency against paracetamol mediated oxidative damage and hepatotoxicity in rats.

### Implication for health policy/practice/research/medical education:

Results demonstrated protective efficiency of red radish seeds and roots against paracetamol mediated hepatotoxicity. This is a promising result for preparation of new drugs against hepatotoxicity.

*Please cite this paper as:* Mohamed DA, Mohamed RS, Essa HA, Abdelgayed SS. Protection efficiency of red radish seeds and roots against paracetamol mediated hepatotoxicity in rats. J Herbm Pharm. 2019;8(4):302-307. doi: 10.15171/jhp.2019.44.

## Introduction

Liver is one of the most vital organs in the body. It is important for maintenance of gastrointestinal homeostasis and body functions. Also, it performs a major role not only in the metabolisms of carbohydrates, proteins and lipids but also in detoxification of xenobiotics (1). So, the maintenance of a healthy liver is crucial for the overall health of an individual but unfortunately there are various environmental and chemical agents such as chemotherapeutic agents and certain antibiotics which cause injury of the liver cells or hepatotoxicity (2). Although the use of acetaminophen or paracetamol is widespread as antipyretic drug but it is considered to be one of the causes of hepatotoxicity which may further develop into liver

failure when overdose used (3). During the metabolism of paracetamol via glucuronidation and sulfation reactions, water-soluble metabolites are produced then excreted by the kidney. Paracetamol is converted by the microsomal P-450 enzyme system to N-acetyl-p-benzoquinone imine (NAPQI) which is then reduced by glutathione (4). But, the overdose of paracetamol leads to over production of NAPQI and depletion of glutathione, then the excess NAPQI can bind to hepatic cell protein and DNA which causes mitochondrial dysfunction and development of acute hepatic necrosis (5). Due to the increasing use of such substances which cause hepatotoxicity with the lack of effective medications for hepatotoxicity, there is a need to find new and safer treatments especially natural one (6).

\*Corresponding author: Rasha S. Mohamed, Tel: +201014196767  
Email: smarasha2005@yahoo.com

Red radish (*Raphanus sativus* L.) is one of the popular vegetables which belongs to the Brassicaceae family. Sprouted seeds and roots of radish are usually eaten raw. Seeds, roots and leaves of red radish are used in salads and as pickles, also for medicinal purposes (7). The phytochemicals content of radish makes it a good alternative treatment for various health problems such as hyperlipidemia, coronary heart diseases and cancer (8) as well as diabetes (7,9). Radish also exhibited antimicrobial effects (10) and nephroprotective impact (11). Flavonoids especially anthocyanins are the most common phytochemicals in the red radish (12). Radish seeds contain flavonoids, steroids, anthraquinoin, alkaloids as well as terpenoids (13), as well as high amounts of calcium, magnesium, potassium, copper, ascorbic acid, vitamin B<sub>6</sub>, folic acid and riboflavin. Due to the high radish contents of the bioactive molecules and from the standpoint of finding natural agents able to protect the liver from the toxicity, the aim of the present study was to evaluate the protection efficiency of crude ethanol extracts of red radish seeds and roots against paracetamol mediated hepatotoxicity in rats.

## Materials and Methods

### Animals

Male Wistar rats (weighing  $148.83 \pm 12.92$  g as mean  $\pm$  SD) were obtained from the animal house of National Research Centre, Cairo, Egypt. The animals were housed individually in stainless steel cages at room temperature with free access to food and water during the experiment.

### Diets

Balanced diet was prepared to contain 10% protein supplemented from casein, 10% corn oil, 23.5% sucrose, 47% maize starch, 5% fiber and 3.5% salt mixture provided by the AIN-93 formulation (15) and 1% vitamin mixture provided by the AIN-93 formulation (15).

### Preparation of crude ethanol extracts of red radish seeds and roots.

Red radish roots were washed, sliced into thin slices then sundried. Dried red radish seeds and roots were powdered and separately extracted with ethanol (95%) in a continuous extraction apparatus (Soxhlet) until exhaustion for preparation of crude ethanol extracts. The solvent was completely removed by evaporation under reduced pressure at a temperature not exceeding 40°C. Crude ethanol extracts of radish dried seeds and roots were kept in deep-freeze till used.

### Determination of total phenolics

Total phenolics were determined colorimetrically in the crude ethanol extracts of red radish seeds and roots using Folin-Ciocalteu reagent (16). Absorbance was measured at 765 nm using UVPC spectrophotometer. The total phenolic content was expressed as gallic acid equivalents

(GAE) in mg/g extract. The results were expressed as mean  $\pm$  standard error (SE).

### Design of the animal experiment

After 1 week of adaptation the animals were divided into four groups (n = 6, each). Group I (normal group) was served as control group. Group II (paracetamol group) was kept untreated for 3 weeks then administered orally after 24 hours fasting with single dose of 2 g paracetamol/kg rat body weight suspended in distilled water. The animals of group III (paracetamol + radish seeds group) were administered orally with crude ethanol extract of radish seeds (300 mg/kg/d) for three weeks then paracetamol using the same mentioned dose, while the animals of group IV (paracetamol + radish roots group) were administered orally with crude extract of radish roots (300 mg/kg/d) for three weeks then paracetamol using the same mentioned dose. All rats were fed on balanced diet all over the study period. During the experiment, body weight and food intake were recorded weekly. At the end of the study total food intake, body weight gain and feed efficiency ratio were calculated. Forty-eight hours after paracetamol administration, the rats were anesthetized using ether and the blood was withdrawn from all rats after an overnight fast. Rats were dissected and liver was immediately separated from each rat and weighed then part of each liver was immersed in 10% formaldehyde solution for histological examination while the other part was immediately analyzed for malondialdehyde (MDA) as indicator of lipid peroxidation according to Ohkawa et al (17) and nitric oxide (NO) according to (18). Serum was analyzed for the activities of aspartate transaminase (AST) and alanine transaminase (ALT) according to Reitman and Frankel (19), total and direct bilirubin according to (20) as well as alkaline phosphatase (ALP) according to Bessey et al (21) and gamma-GT ( $\gamma$ -GT) according to Szasz (22).

### Statistical analysis

Statistical analysis was done using SPSS version 22. The results were expressed as mean  $\pm$  SE and analyzed statistically using one-way analysis of variance (ANOVA) followed by Duncan test. The statistical significance of difference was taken as  $P \leq 0.05$ .

### Results

Total phenolic content of crude ethanol extracts of red radish seeds and roots were observed as  $57.3 \pm 0.523$  and  $73.3 \pm 4.112$  mg GAE/g extract, respectively.

### Liver functions and oxidative markers of liver tissue

Concerning the liver enzymes (AST, ALT, ALP and  $\gamma$ -GT) as well as total and direct bilirubin, data tabulated in Table 1, showing that administration of paracetamol induced significant ( $P \leq 0.05$ ) elevation in all liver enzymes (AST, ALT, ALP and  $\gamma$ -GT) as well as total and direct bilirubin.

**Table 1.** Liver functions and oxidative markers of liver tissues in experimental groups

Parameters	Groups			
	Normal	Paracetamol	Paracetamol + radish seeds crude ethanol extract	Paracetamol + radish roots crude ethanol extract
<b>Liver functions</b>				
AST (U/L)	20.17 <sup>a</sup> ± 1.35	85.33 <sup>d</sup> ± 2.76	50.67 <sup>c</sup> ± 1.36	34.33 <sup>b</sup> ± 1.76
ALT (U/L)	15.17 <sup>a</sup> ± 1.22	50.67 <sup>c</sup> ± 4.98	27.33 <sup>b</sup> ± 0.76	17.67 <sup>a</sup> ± 1.33
ALP (U/L)	193.39 <sup>a</sup> ± 4.13	243.83 <sup>b</sup> ± 12.22	208.57 <sup>a</sup> ± 7.98	213.94 <sup>a</sup> ± 3.79
γ-GT (U/L)	10.08 <sup>a</sup> ± 1.03	34.50 <sup>c</sup> ± 1.61	16.17 <sup>b</sup> ± 0.61	14.58 <sup>b</sup> ± 0.78
Total bilirubin (mg/dL)	2.31 <sup>a</sup> ± 0.07	4.35 <sup>c</sup> ± 0.36	2.44 <sup>a</sup> ± 0.16	3.18 <sup>b</sup> ± 0.21
Direct bilirubin (mg/dL)	1.83 <sup>a</sup> ± 0.10	2.61 <sup>b</sup> ± 0.29	2.10 <sup>ab</sup> ± 0.14	2.31 <sup>ab</sup> ± 0.09
<b>Oxidative markers of liver tissues</b>				
MDA (nmol/g tissue)	8.30 <sup>a</sup> ± 0.35	11.55 <sup>b</sup> ± 0.44	10.45 <sup>b</sup> ± 0.57	10.28 <sup>b</sup> ± 0.38
Nitric oxide (umol/g tissue)	54.82 <sup>b</sup> ± 0.74	68.43 <sup>c</sup> ± 1.89	56.17 <sup>b</sup> ± 1.05	50.72 <sup>a</sup> ± 1.15

AST: aspartate transaminase; ALT: alanine transaminase; ALP: alkaline phosphatase; γ-GT: Gama-GT; MDA: malondialdehyde.

In each row, same letters mean non-significant difference; different letters mean the significance among the tested groups. The confidence level is 95%.

On the other hand, these elevations of liver parameters were suppressed via the orally administration either of radish seeds extract or radish roots extract. On the same approach, rats that were treated with paracetamol only exhibited significant ( $P \leq 0.05$ ) rising in both MDA and nitric oxide levels (as oxidative markers) when compared to the normal rats. While, rats that were treated in advance with either radish seeds extract or radish roots extract recorded MDA and nitric oxide levels lower than those of rats that treated with paracetamol only.

#### Growth performance parameters

The growth performance parameters (body weight gain, total food intake, feed efficiency ratio, liver weight and relative liver weight) of normal rats, rats that were treated on 22nd day with paracetamol only and rats that treated in advance with either radish seeds extract or radish roots extract were summarized in Table 2. It was noticed that there were not significant ( $P > 0.05$ ) differences in the final body weight and the total food intake between the mentioned groups. The liver weight and relative liver

weight of the rats treated with paracetamol were higher than those of normal rats.

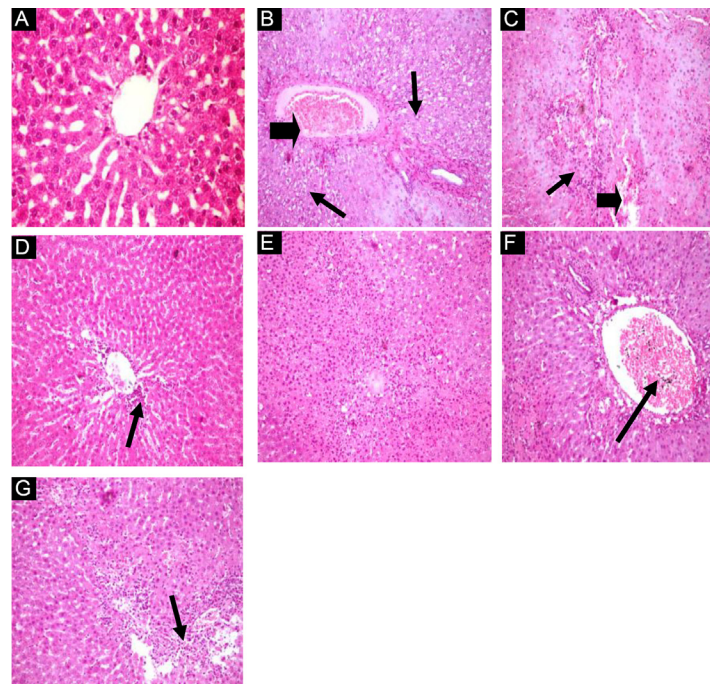
#### Histopathological examination

Liver of normal control group (Figure 1A) showed normal hepatic parenchyma, normal hepatic cords and blood sinusoids (H&E, x400) (Lesion score: 0). Liver of paracetamol control group (Figure 1B) showed vacuolated hepatocytes (arrows) together with portal tract changes also congestion in the hepatoportal blood vessel (arrow head) (H&E, x400), (Lesion score: +++). Liver of paracetamol group (Figure 1C) showed multiple focal areas of hepatic necrosis infiltrated with mononuclear cells (arrows) together with hemorrhagic areas (arrow head) (H&E, x400) (Lesion score: +++). Liver of rats given ethanol extract of red radish seeds and paracetamol (Figure 1D) showed improved hepatic parenchyma with minimal changes in the portal tract and few mononuclear cells infiltrations (arrow) (H&E, x400), (Lesion score: +). Also livers of the rats given ethanol extract of red radish seeds and paracetamol showed improved hepatic

**Table 2.** Growth performance parameters of the experimental groups

Parameters	Groups			
	Normal	Paracetamol	Paracetamol + Radish seeds crude ethanol extract	Paracetamol + Radish roots crude ethanol extract
Initial body weight (g)	148.83 <sup>a</sup> ± 7.00	148.67 <sup>a</sup> ± 4.53	149.00 <sup>a</sup> ± 5.19	148.83 <sup>a</sup> ± 6.43
Final body weight (g)	193.83 <sup>a</sup> ± 7.23	204.83 <sup>a</sup> ± 4.98	200.83 <sup>a</sup> ± 5.28	199.67 <sup>a</sup> ± 8.08
Body weight gain (g)	45.00 <sup>a</sup> ± 1.15	56.17 <sup>b</sup> ± 1.33	51.83 <sup>b</sup> ± 1.72	50.83 <sup>ab</sup> ± 3.47
Total food intake (g)	298.17 <sup>a</sup> ± 5.39	303.83 <sup>a</sup> ± 6.32	299.00 <sup>a</sup> ± 6.99	303.00 <sup>a</sup> ± 5.15
Feed efficiency ratio	0.15 <sup>a</sup> ± 0.002	0.18 <sup>c</sup> ± 0.005	0.17 <sup>bc</sup> ± 0.005	0.17 <sup>ab</sup> ± 0.009
Liver weight (g)	5.07 <sup>a</sup> ± 0.25	6.10 <sup>ab</sup> ± 0.54	6.75 <sup>b</sup> ± 0.29	6.78 <sup>b</sup> ± 0.47
Liver %	2.66 <sup>a</sup> ± 0.025	3.13 <sup>ab</sup> ± 0.094	3.31 <sup>b</sup> ± 0.049	3.35 <sup>b</sup> ± 0.112

In each row, same letters mean non-significant difference; different letters mean the significance among the tested groups. The confidence level is 95%.



**Figure 1.** Histopathological changes of the liver (liver sections H&E, x400) in different groups; (A) Normal group, (B & C) Paracetamol groups (The arrow on B shows vacuolated hepatocytes and the arrow head shows congested hepatoportal blood vessel. The arrow on C shows necrosis and the arrow head shows hemorrhagic areas), (D & E) Paracetamol and ethanol extract of red radish seeds groups (The arrow on D shows few mononuclear cells infiltrations), (F & G) Paracetamol and ethanol extract of red radish roots groups (The arrow on F shows congested hepatoportal blood vessel and the arrow on G shows minimal leucocytic cells infiltration).

parenchyma (Figure 1E) with low hepatic necrosis (H&E, x400) (Lesion score: +). Liver of rats given ethanol extract of red radish root and paracetamol (Figure 1F) showed improved hepatic parenchyma with minimal changes in the portal tract and congested hepatoportal blood vessels (arrow) (H&E, x400) (Lesion score: ++). Also, liver of the rats given ethanol extract of red radish root and paracetamol (Figure 1G) showed improved hepatic parenchyma with minimal leucocytic cells infiltration (arrow), (H&E, x400). (Lesion score: ++).

### Discussion

Liver is susceptible to damage by several drugs and other xenobiotics which are metabolized by liver. Xenobiotics concentrate in the blood and reach to liver from the gastrointestinal and spleen through the portal veins. These drugs and xenobiotics turn to other metabolites which react with the cellular macromolecules (proteins, lipids, and nucleic acids) resulting in liver injury by oxidative stress, protein dysfunction, lipid peroxidation and damage of DNA (2). Paracetamol is one of the most common painkillers which cause hepatotoxicity via its metabolites when used at overdose. NAPQI, the metabolite of paracetamol is responsible for cellular damage which leads to changes in the cell permeability and loss of cellular integrity (23). Also an inhibition in NADH and succinate dehydrogenase function is caused by NAPQI. Disturbance in the homeostasis results in accumulation of intracellular

Ca<sup>2+</sup> and elevation of catabolic enzymes which causes cell death. In such case, reactive oxygen species, nitric oxide, peroxynitrite derivatives, lipid peroxidation and protein nitrates have roles in hepatotoxicity (24). Several studies demonstrated that paracetamol mediated oxidative damage and hepatotoxicity in rats and mice, resulting in enhancement of the liver parameters (25-27). In the present study oral administration of a single dose of 2 g paracetamol/kg body wt on the 22nd day induced oxidative stress and toxicity in the liver. The evidence for this was the increase in the activities of liver enzymes as well as the levels of MDA and NO in rats treated with paracetamol. Achliya et al (28) declared that the damage of parenchymal hepatic cells and the membranes results in releasing of the liver enzymes into the serum.

In the present study crude ethanol extracts of red radish seeds and roots were rich in phenolic compounds. The present results are in agreement with the results of Syed et al (29) who reported that phenolic content of radish ethanol extract was 70.1 GAE/g of extract. Due to radish content of the bioactive compounds that have antioxidant activity, it has been postulated that radish has a positive role in protecting the liver from oxidative damage and hepatotoxicity. Indeed, the results of the present study revealed that the pretreatment with crude ethanol extract of either seeds or roots of red radish suppressed the elevations in liver functions, MDA and NO. This hepatoprotective efficiency of radish seeds and roots may

be due to the presence of some compounds such as allyl isothiocyanate (30). Allyl isothiocyanate has been shown to protect the liver from the toxicity caused by carbon tetrachloride. Also Syed et al (29) reported that radish contains quercetin, polyphenols and anthocyanins by which radish can ameliorate the elevations in MDA and NO, reduce the oxidation through increasing the activities of antioxidant enzymes (glutathione S-transferase and superoxide dismutase) and suppress the stimulants of oxidation (nitric oxide synthase, cyclooxygenase 2, lipoxygenase 2 and xanthine oxidase). Adeneye and Olagunju (31) and Modo et al (32) disclosed that vitamin C showed protective role against paracetamol mediated hepatotoxicity. In addition, Cristani et al (33) and Aswathy and Murugan (34) reported that anthocyanins exhibited hepatoprotective impact. So, the hepatoprotective efficiency of radish may be also attributed to its content of vitamin c and anthocyanins, both of which have antioxidant activities

### Conclusion

Results of the present study illustrated that crude extracts of either seeds or roots of red radish at 300 mg/kg/d dose exhibited protection efficiency against paracetamol mediated oxidative damage and hepatotoxicity. Therefore, it might be beneficial to incorporate seeds and roots of red radish in the daily diets to protect the liver from the oxidative damage and hepatotoxicity caused by the excessive use of painkillers.

### Authors' contributions

Designing the study and preparation of plant extracts were done by DAM. RSM and HAE equally contributed in the animal experiment, analysis of serum and tissue samples and data analysis. The histological examination was done by SSA. All authors contributed in the preparation of the manuscript. Also, all authors read and approved the final manuscript. RSM submitted the manuscript.

### Conflict of interests

Authors declare no conflict of interests.

### Ethical considerations

The animal experiment has been carried out according to the Ethics Committee, National Research Centre, Cairo, Egypt and followed the recommendations of the National Institutes of Health Guide for Care and Use of Laboratory Animals (Publication No. 85-23, revised 1985).

### Funding/Support

None.

### References

1. Azab A, Nassar A, Azab AN. Anti-Inflammatory Activity of Natural Products. *Molecules*. 2016;21(10). doi: 10.3390/molecules21101321.

2. Gulati K, Reshi MR, Rai N, Ray A. Hepatotoxicity: Its mechanisms, experimental evaluation and protective strategies. *Am J Pharmacol*. 2018;1(1):1004.
3. Abdelazim SA, Abdelrahman MT, Said MM, Khattab A. Protective effect of *Moringa peregrina* leaves extract on acetaminophen-induced liver toxicity in albino rats. *Afr J Tradit Complement Altern Med*. 2017;14(2):206-16. doi: 10.21010/ajtcam.v14i2.22.
4. Madkour FF, Abdel-Daim MM. Hepatoprotective and antioxidant activity of *Dunaliella salina* in paracetamol-induced acute toxicity in rats. *Indian J Pharm Sci*. 2013;75(6):642-8.
5. Elmhdwi MF, Muftah SM, El Tumi SG, Elslimani F. Hepatoprotective effect of *Ecballium Elaterium* fruit juice against paracetamol induced hepatotoxicity in male albino rats. *Int Curr Pharm J*. 2014;3(5):270-4. doi: 10.3329/icpj.v3i5.18535.
6. Moshaei-Nezhad P, Iman M, Faed Maleki F, Khamesipour A. Hepatoprotective effect of *Descurainia sophia* seed extract against paracetamol-induced oxidative stress and hepatic damage in mice. *J Herbm Pharm*. 2018;7(4):267-72. doi: 10.15171/jhp.2018.40.
7. Banihani SA. Radish (*Raphanus sativus*) and diabetes. *Nutrients*. 2017;9(9). doi: 10.3390/nu9091014.
8. Curtis IS. The noble radish: past, present and future. *Trends Plant Sci*. 2003;8(7):305-7. doi: 10.1016/S1360-1385(03)00127-4.
9. Ahmed OM, Abdel-Reheim ES, Ashour MB, Fahim HI, Mohamed HH. Efficacies of *Eruca sativa* and *Raphanus sativus* seeds' oils in streptozotocin induced diabetic rats. *Int J Clin Endocrinol Metab*. 2016;2(1):34-43. doi: 10.17352/ijcem.000020.
10. Rakhmawati R, Anggarwulan E, Retnaningtyas E. Potency of Lobak leaves (*Raphanus sativus* L. var. Hortensis Back) as anticancer and antimicrobial candidates. *Biodiversitas*. 2009;10(3):158-62. doi: 10.13057/biodiv/d100310.
11. Talele BD, Mahajan RT, Chopda MZ, Nemade NV. Nephroprotective plants: a review. *Int J Pharm Pharm Sci*. 2012;4(1):8-16.
12. Lin LZ, Sun J, Chen P, Harnly JA. LC-PDA-ESI/MS(n) identification of new anthocyanins in purple Bordeaux radish (*Raphanus sativus* L. variety). *J Agric Food Chem*. 2011;59(12):6616-27. doi: 10.1021/jf200571a.
13. Khamees AH. Phytochemical and pharmacological analysis for seeds of two varieties of Iraqi *Raphanus sativus*. *Int J Pharm Sci Rev Res*. 2017;43(1):237-42.
14. Jan M, Badar A. Effect of crude extract of *Raphanus sativus* roots on isolated trachea of albino rat. *Pak J Physiol*. 2012;8(1):23-6.
15. Reeves PG, Nielsen FH, Fahey GC Jr. AIN-93 purified diets for laboratory rodents: final report of the American Institute of Nutrition ad hoc writing committee on the reformulation of the AIN-76A rodent diet. *J Nutr*. 1993;123(11):1939-51. doi: 10.1093/jn/123.11.1939.
16. Singleton VL, Orthofer R, Lamuela-Raventos RM. Analysis of total phenols and other oxidation substrates and antioxidants by means of folin-ciocalteu reagent. *Methods Enzymol*. 1999;299:152-78. doi: 10.1016/s0076-6879(99)99017-1.

17. Ohkawa H, Ohishi N, Yagi K. Assay for lipid peroxides in animal tissues by thiobarbituric acid reaction. *Anal Biochem.* 1979;95(2):351-8. doi: 10.1016/0003-2697(79)90738-3.
18. Montgomery HAC, Dymock J. The determination of nitrite in water. *Analyst.* 1961;86:414-6.
19. Reitman S, Frankel S. A colorimetric method for the determination of serum glutamic oxalacetic and glutamic pyruvic transaminases. *Am J Clin Pathol.* 1957;28(1):56-63. doi: 10.1093/ajcp/28.1.56.
20. Balistreri WF, Shaw LM. Liver function. In: Tietz NW, ed. *Fundamentals of Clinical Chemistry.* 3rd ed. Philadelphia: WB Saunders; 1987:729-61.
21. Bessey OA, Lowry OH, Brock MJ. A method for the rapid determination of alkaline phosphates with five cubic millimeters of serum. *J Biol Chem.* 1946;164:321-9.
22. Szasz G. A kinetic photometric method for serum gamma-glutamyl transpeptidase. *Clin Chem.* 1969;15(2):124-36.
23. Bigoniya P, Singh CS, Shukla AK. A comprehensive review of different liver toxicants used in experimental pharmacology. *Int J Pharm Sci Drug Res.* 2009;1(3):124-35.
24. Jaeschke A, Abbas B, Zabel M, Hopmans EC, Schouten S, Sinninghe Damstea JS. Molecular evidence for anaerobic ammonium-oxidizing (anammox) bacteria in continental shelf and slope sediments off northwest Africa. *Limnol Oceanogr.* 2010;55(1):365-76. doi: 10.4319/lo.2010.55.1.0365.
25. Talluri MR, Gummadi VP, Battu GR. Chemical Composition and Hepatoprotective Activity of *Saponaria officinalis* on Paracetamol-induced Liver Toxicity in Rats. *Pharmacogn J.* 2018;10(6):1196-201. doi: 10.5530/pj.2018.6.205.
26. Uchendu IK, Agu CE, Orji OC, Nnedu EB, Arinze C, Uchenna AC, et al. Effect of tomato (*Lycopersicon esculentum*) extract on acetaminophen - induced acute hepatotoxicity in albino Wistar rat. *Bioequiv Bioavailab Int J.* 2018;2(1). doi: 10.23880/beba-16000119.
27. Papackova Z, Heczko M, Dankova H, Sticova E, Lodererova A, Bartonova L, et al. Silymarin prevents acetaminophen-induced hepatotoxicity in mice. *PLoS One.* 2018;13(1):e0191353. doi: 10.1371/journal.pone.0191353.
28. Achliya GS, Wadodkar SG, Dorle AK. Evaluation of hepatoprotective effect of Amalkadi Ghrita against carbon tetrachloride-induced hepatic damage in rats. *J Ethnopharmacol.* 2004;90(2-3):229-32. doi: 10.1016/j.jep.2003.09.037.
29. Syed SN, Rizvi W, Kumar A, Khan AA, Moin S, Ahsan A. In vitro antioxidant and in vivo hepatoprotective activity of leave extract of *Raphanus sativus* in rats using CCL4 model. *Afr J Tradit Complement Altern Med.* 2014;11(3):102-6. doi: 10.4314/ajtcam.v11i3.15.
30. Ahn M, Kim J, Bang H, Moon J, Kim GO, Shin T. Hepatoprotective effects of allyl isothiocyanate against carbon tetrachloride-induced hepatotoxicity in rat. *Chem Biol Interact.* 2016;254:102-8. doi: 10.1016/j.cbi.2016.05.037.
31. Adeneye A, Olagunju J. Protective effect of oral Ascorbic Acid (Vitamin C) against Acetaminophen-induced hepatic injury in rats. *Afr J Biomed Res.* 2008;11(2):183-90. doi: 10.4314/ajbr.v11i2.50704.
32. Modo E, Okwandu N, Dongo B. Comparative effects of vitamin C and vitamin E pre-treatment in acute paracetamol induced toxicity on the liver of rats. *World J Pharm Sci.* 2015;3(3):407-12.
33. Cristani M, Speciale A, Mancari F, Arcoraci T, Ferrari D, Fratantonio D, et al. Protective activity of an anthocyanin-rich extract from bilberries and blackcurrants on acute acetaminophen-induced hepatotoxicity in rats. *Nat Prod Res.* 2016;30(24):2845-9. doi: 10.1080/14786419.2016.1160235.
34. Aswathy JM, Murugan K. Hepato-protective efficacy of purified anthocyanin from *Begonia* species on albino rats intoxicated with carbon tetrachloride and paracetamol. *Int J Pharma Res Health Sci.* 2018;6(2):2507-16. doi: 10.21276/ijprhs.2018. 2018. 02.30.